



UPPSALA
UNIVERSITET

^{18}F -FDG PET-CT i klinik

Cecilia Wassberg

Överläkare, Bild och funktionsmedicin


Akademiska Sjukhuset, Uppsala



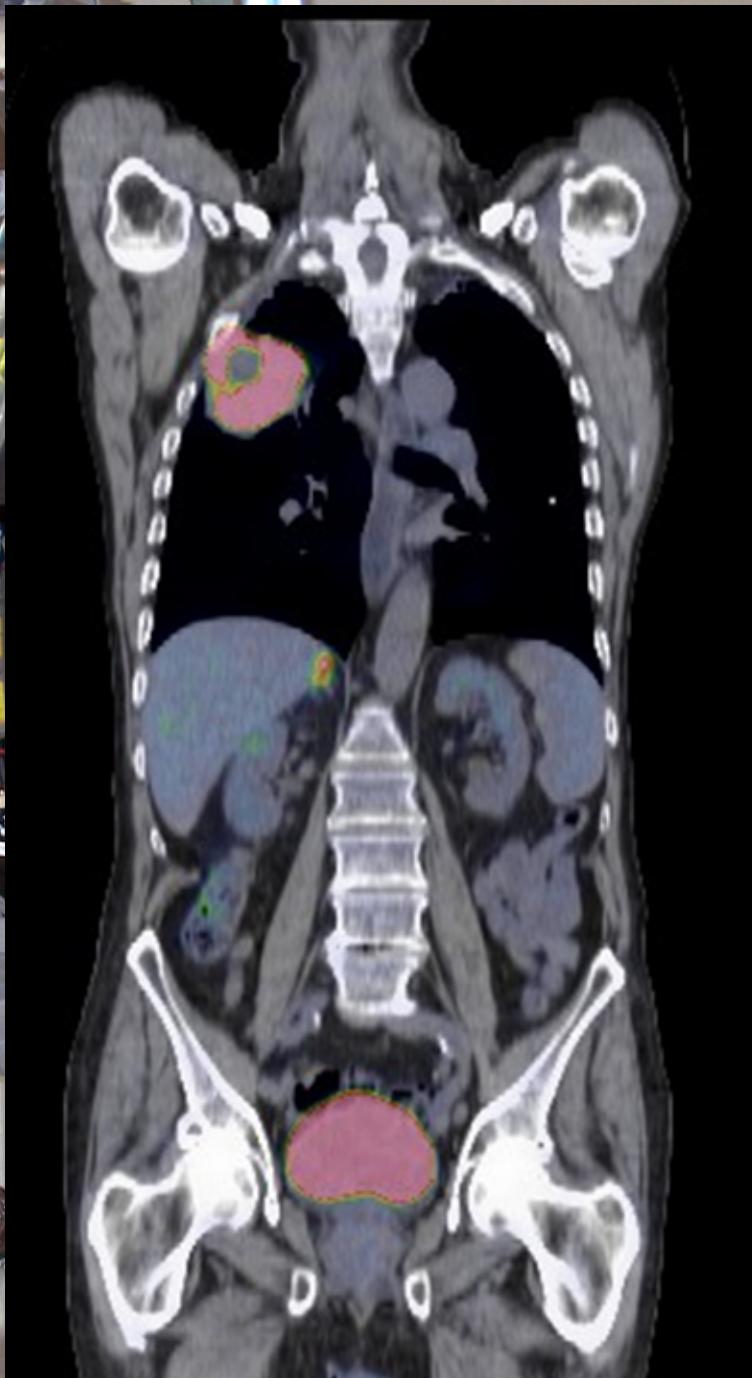
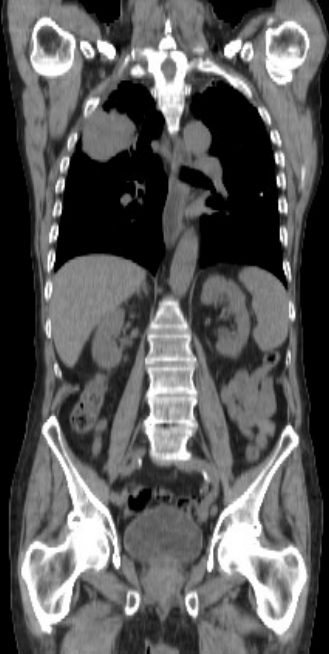
Röntgenveckan 2013



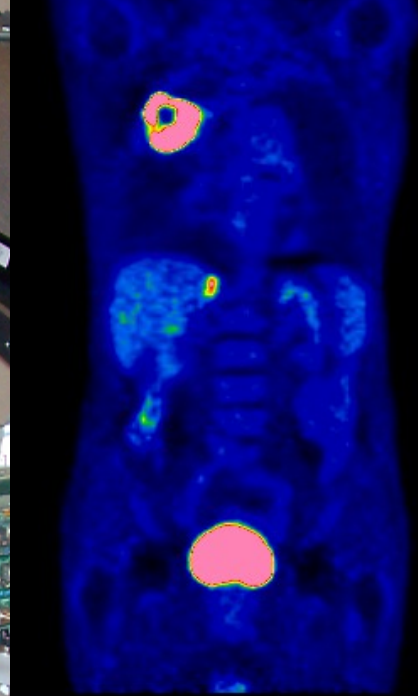
AKADEMISKA
SJUKHUSET



ANATOMI

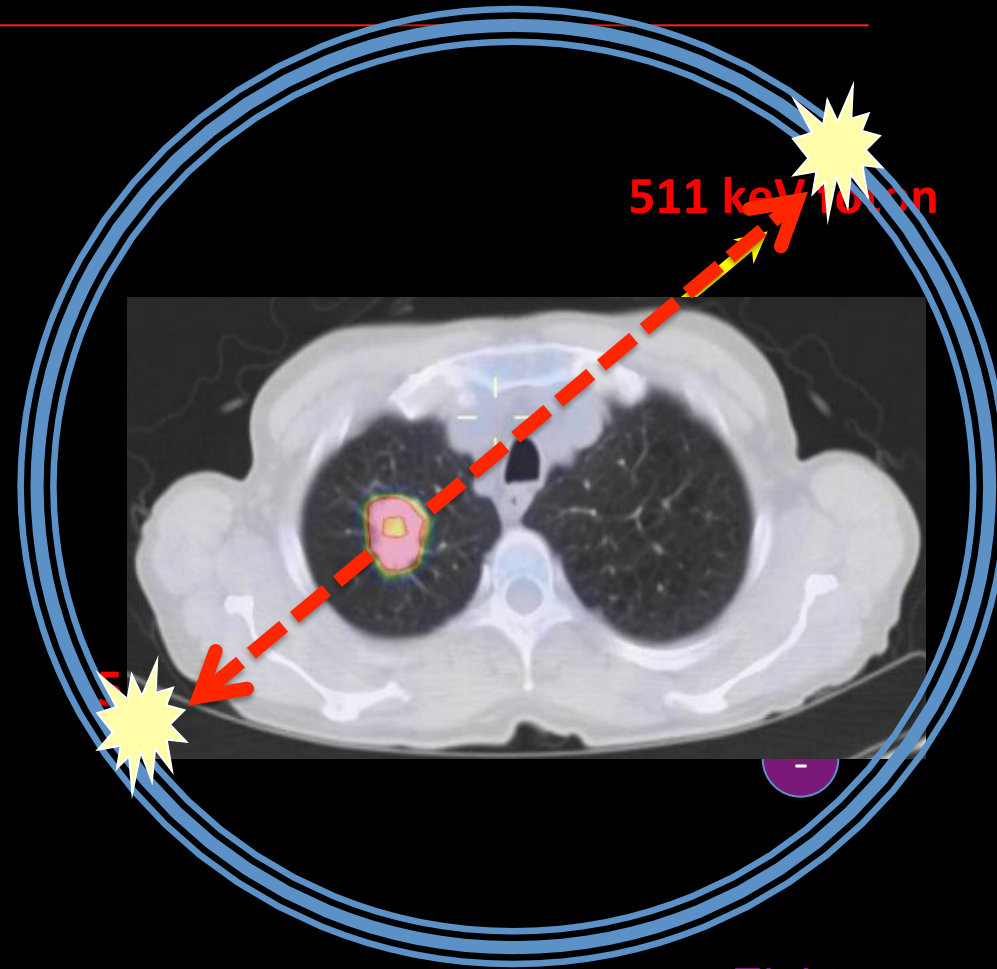
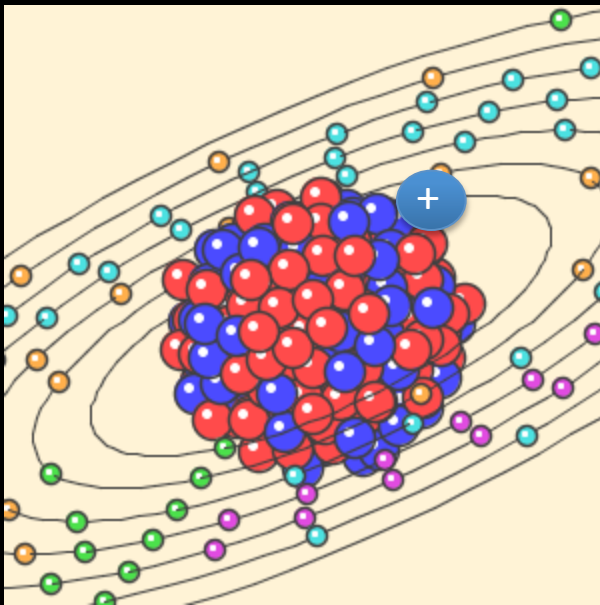


FUNKTION



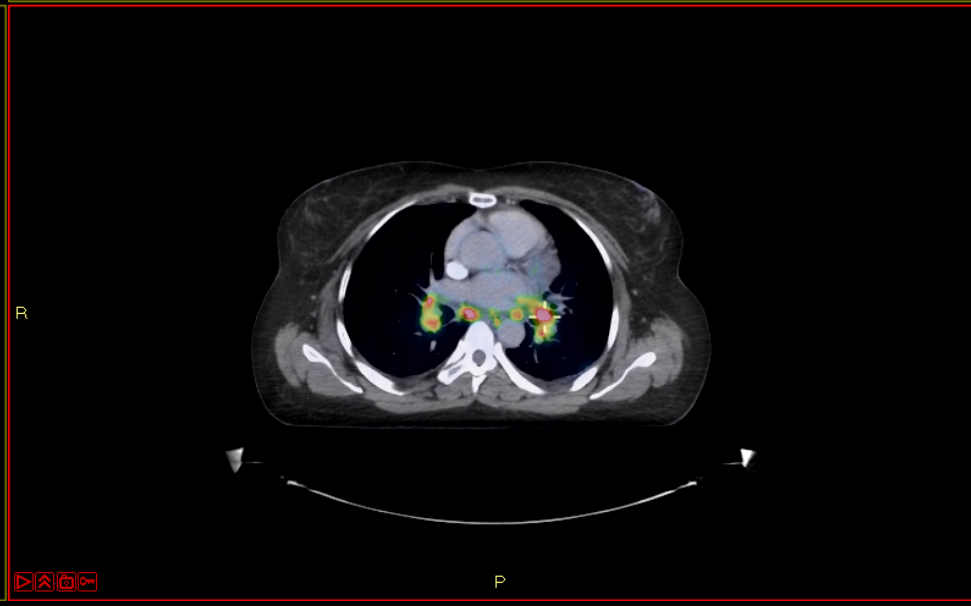
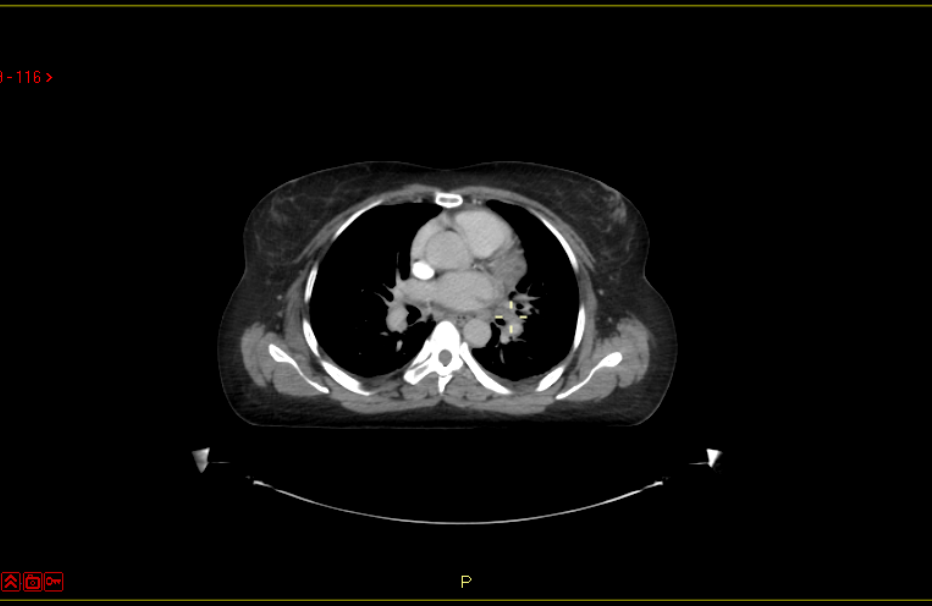
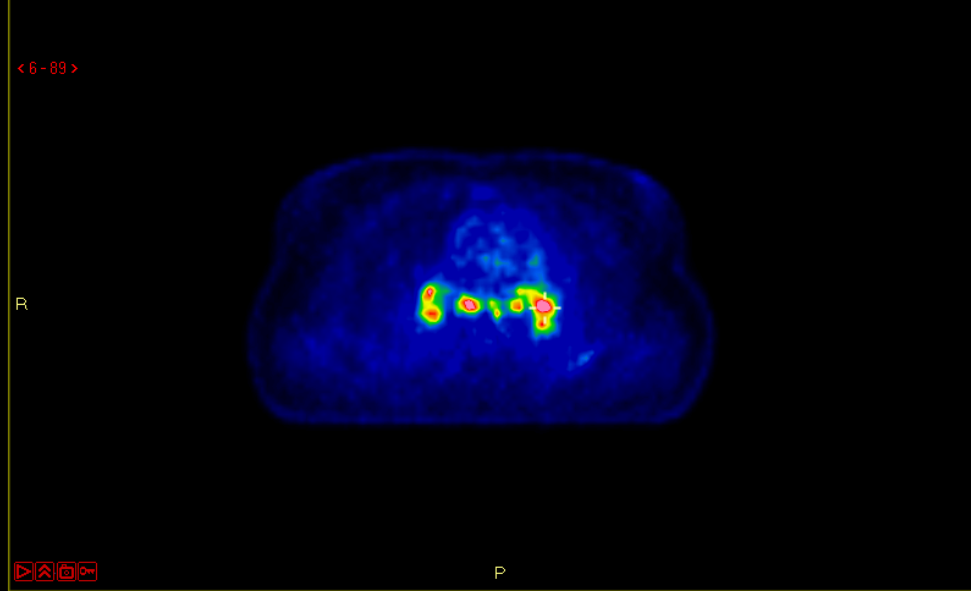
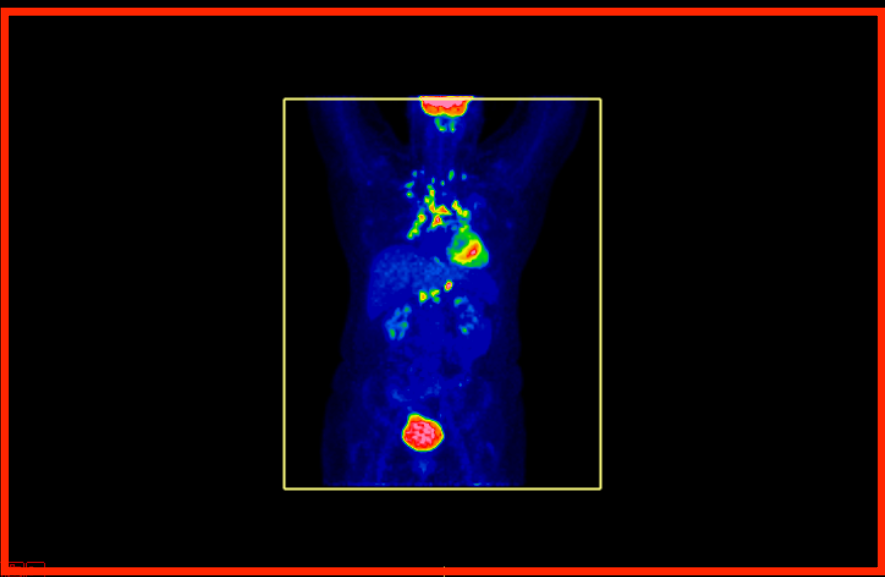
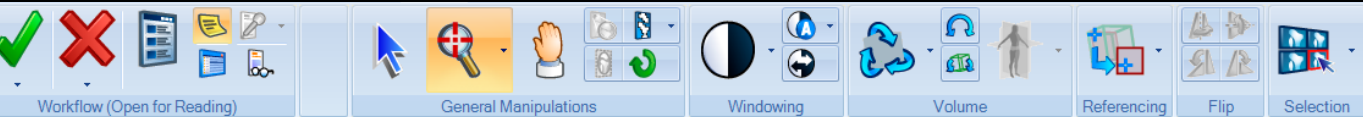Positronannihilation

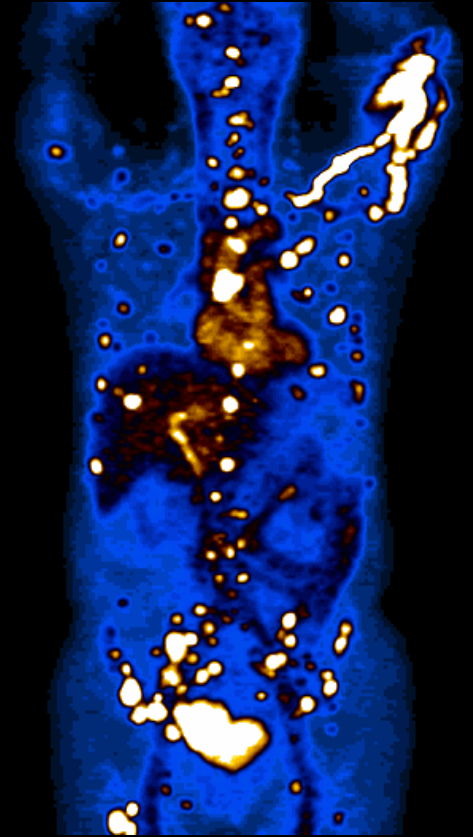
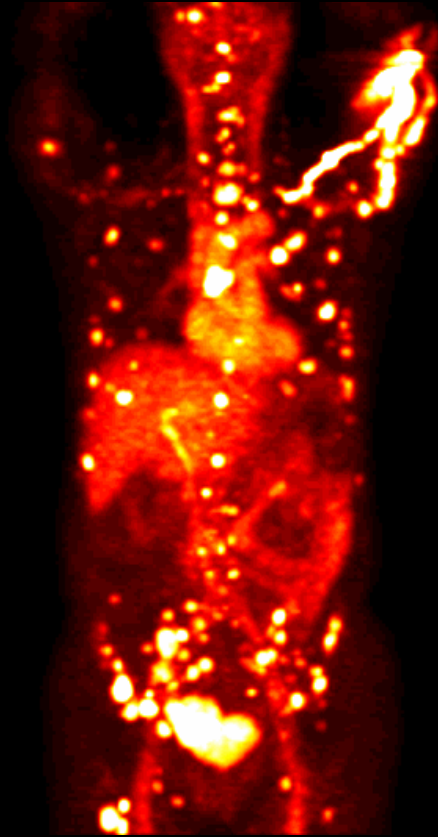
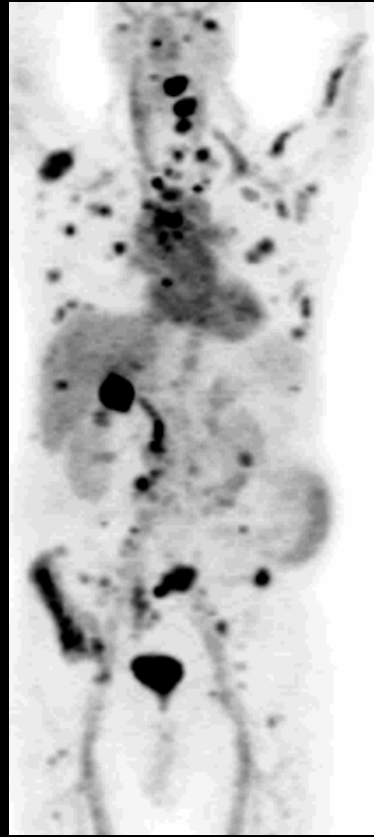
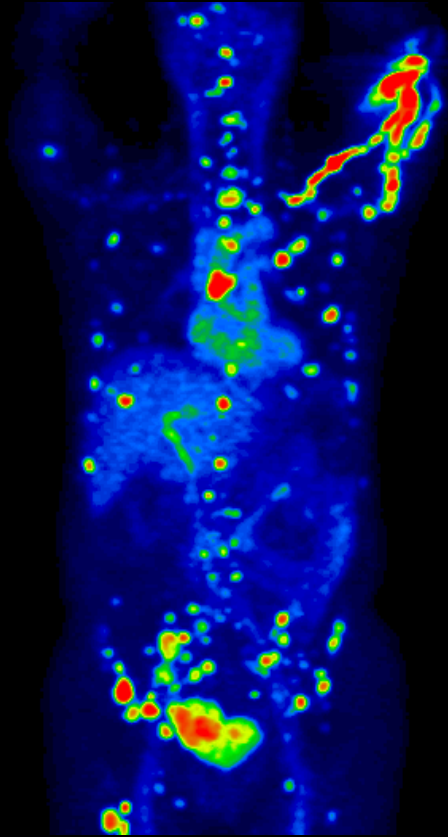
Positron



Elektron

Coincidence detection





Workflow (Open for Reading)

General Manipulations

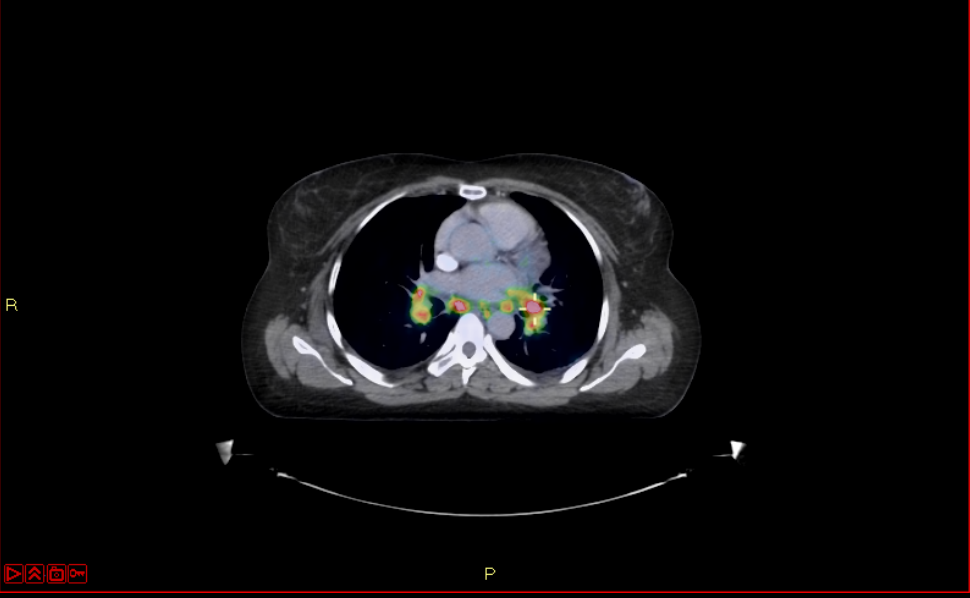
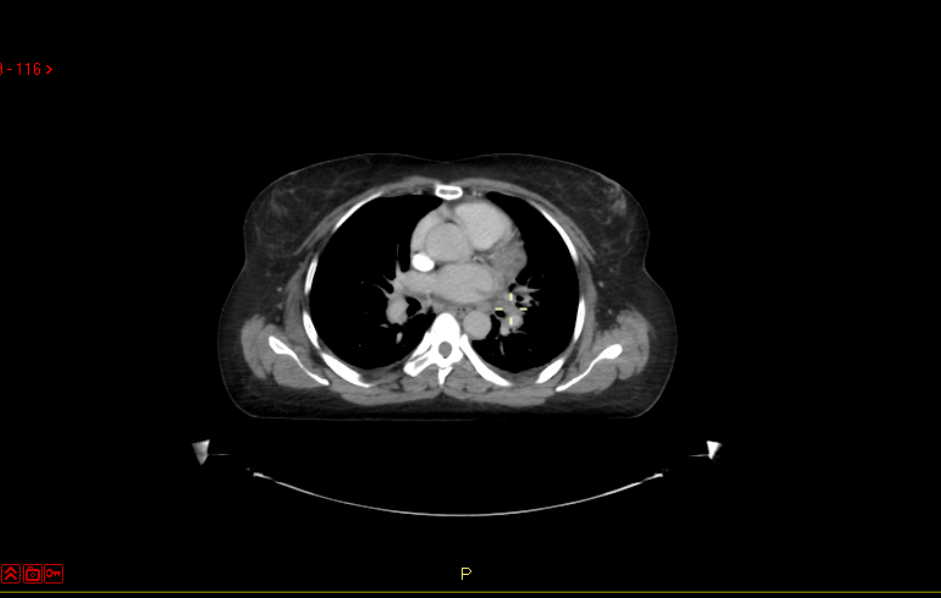
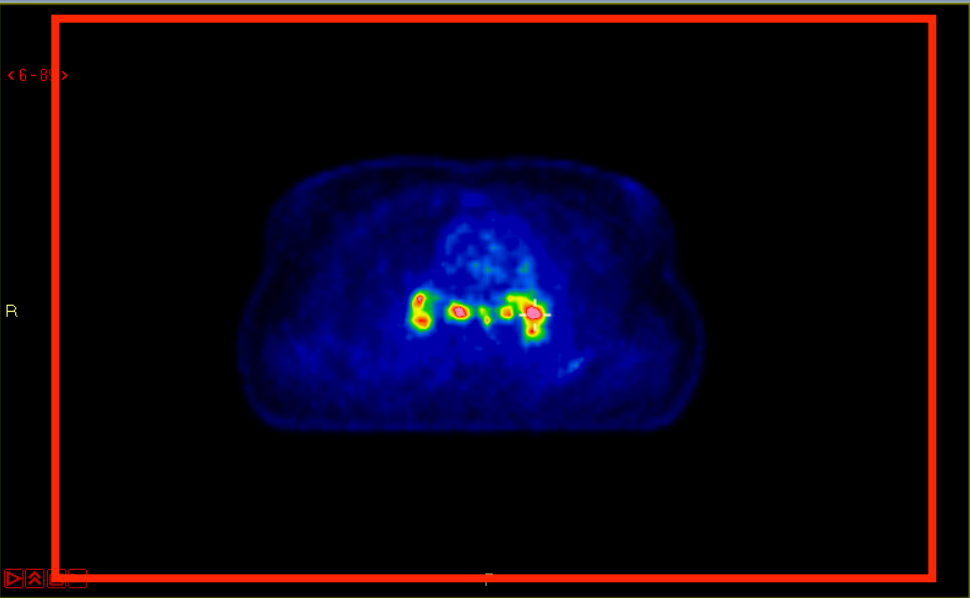
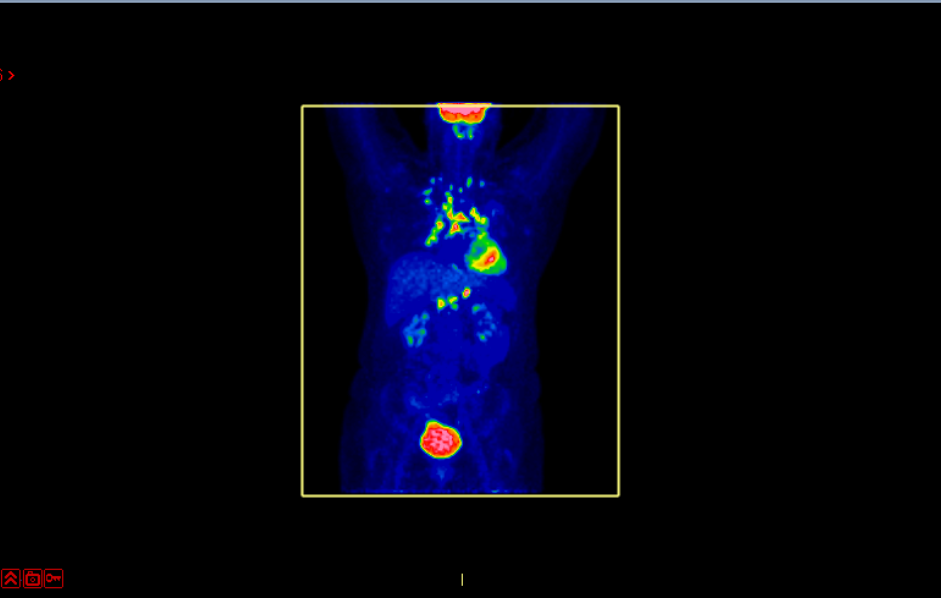
Windowing

Volume

Referencing

Flip

Selection



Workflow (Open for Reading)

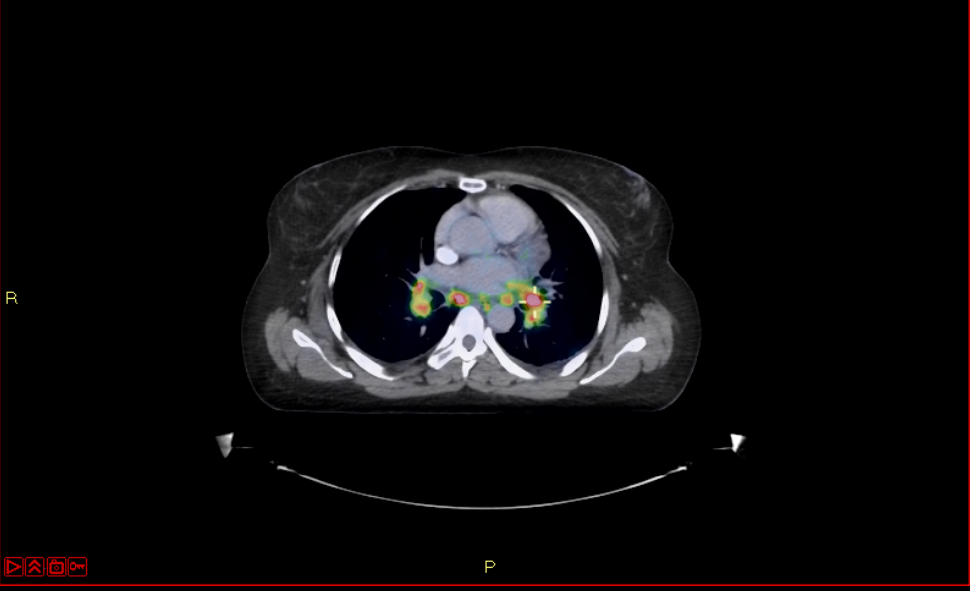
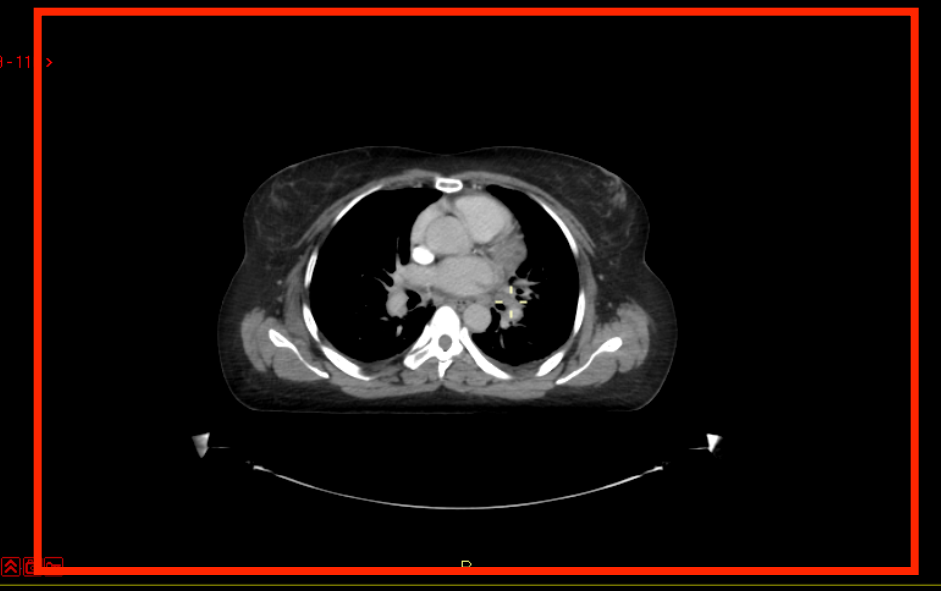
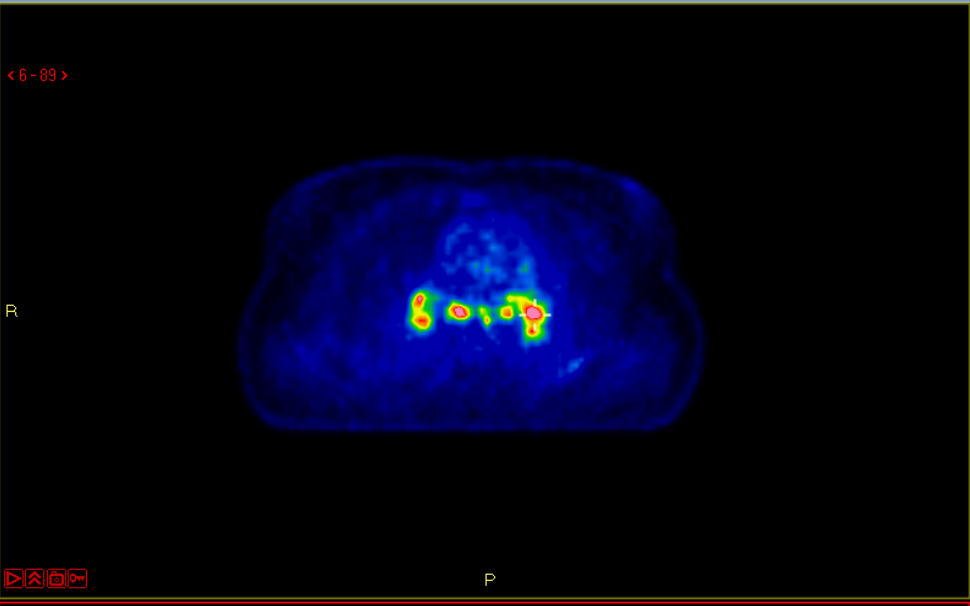
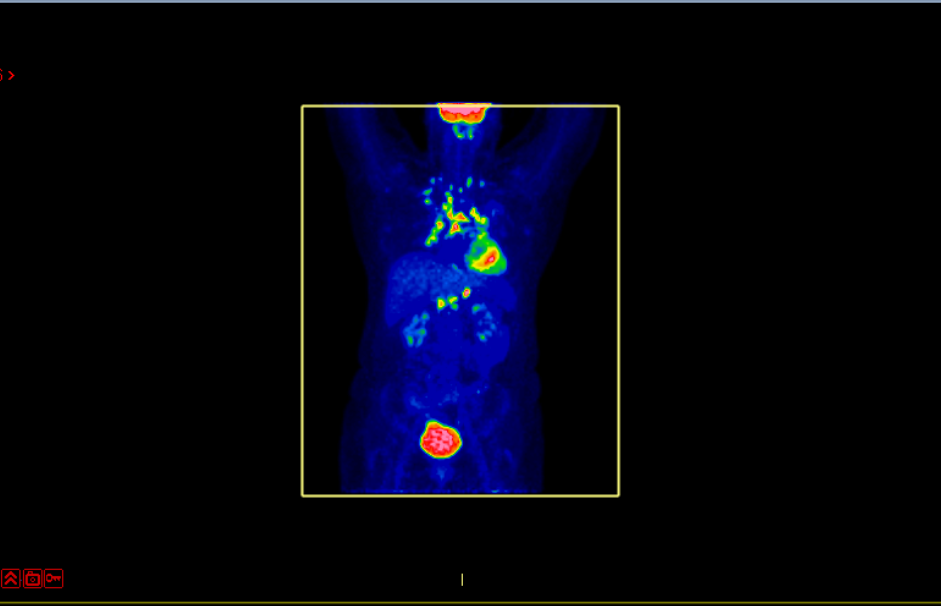
General Manipulations

Windowing

Volume

Referencing

Flip Selection



Workflow (Open for Reading)

General Manipulations

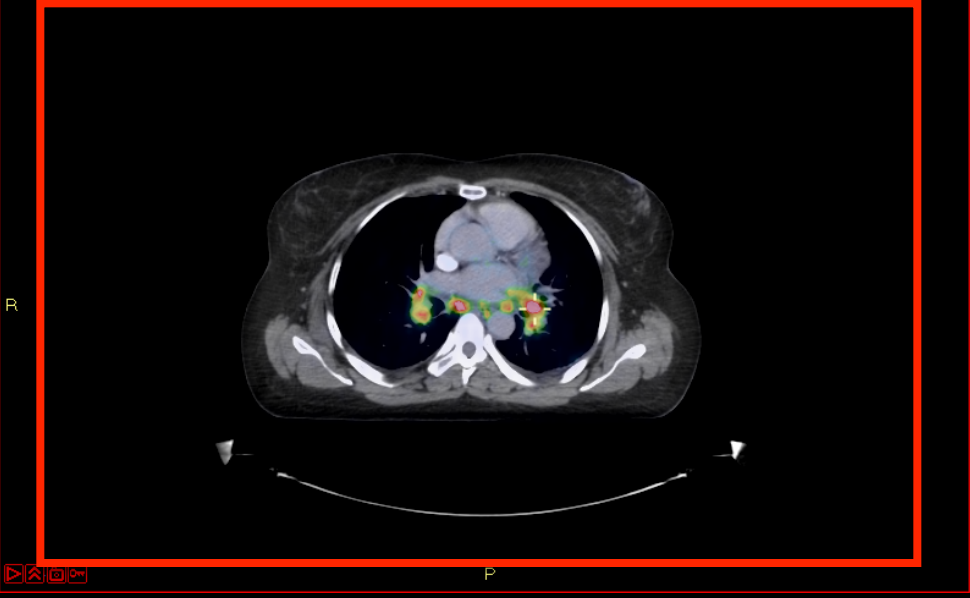
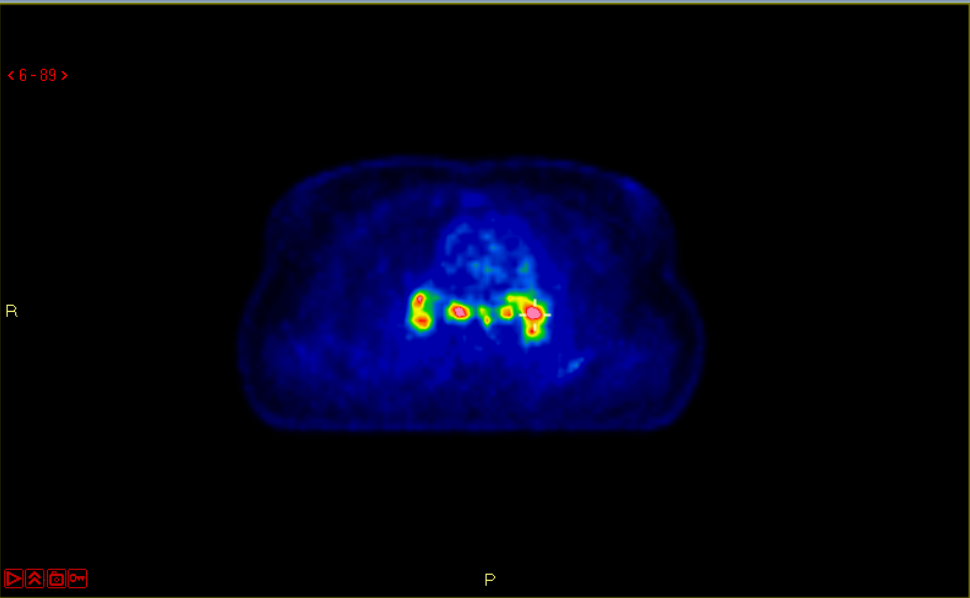
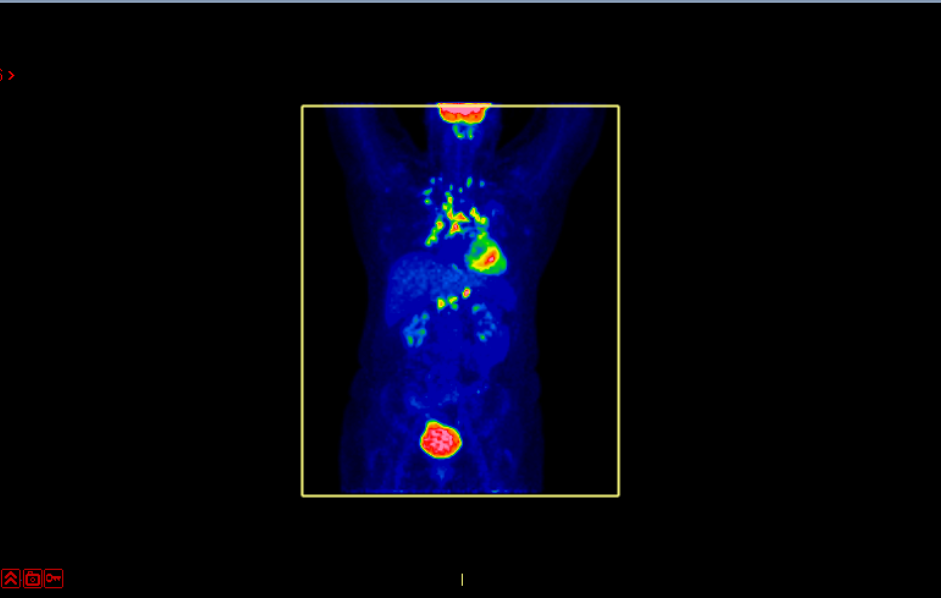
Windowing

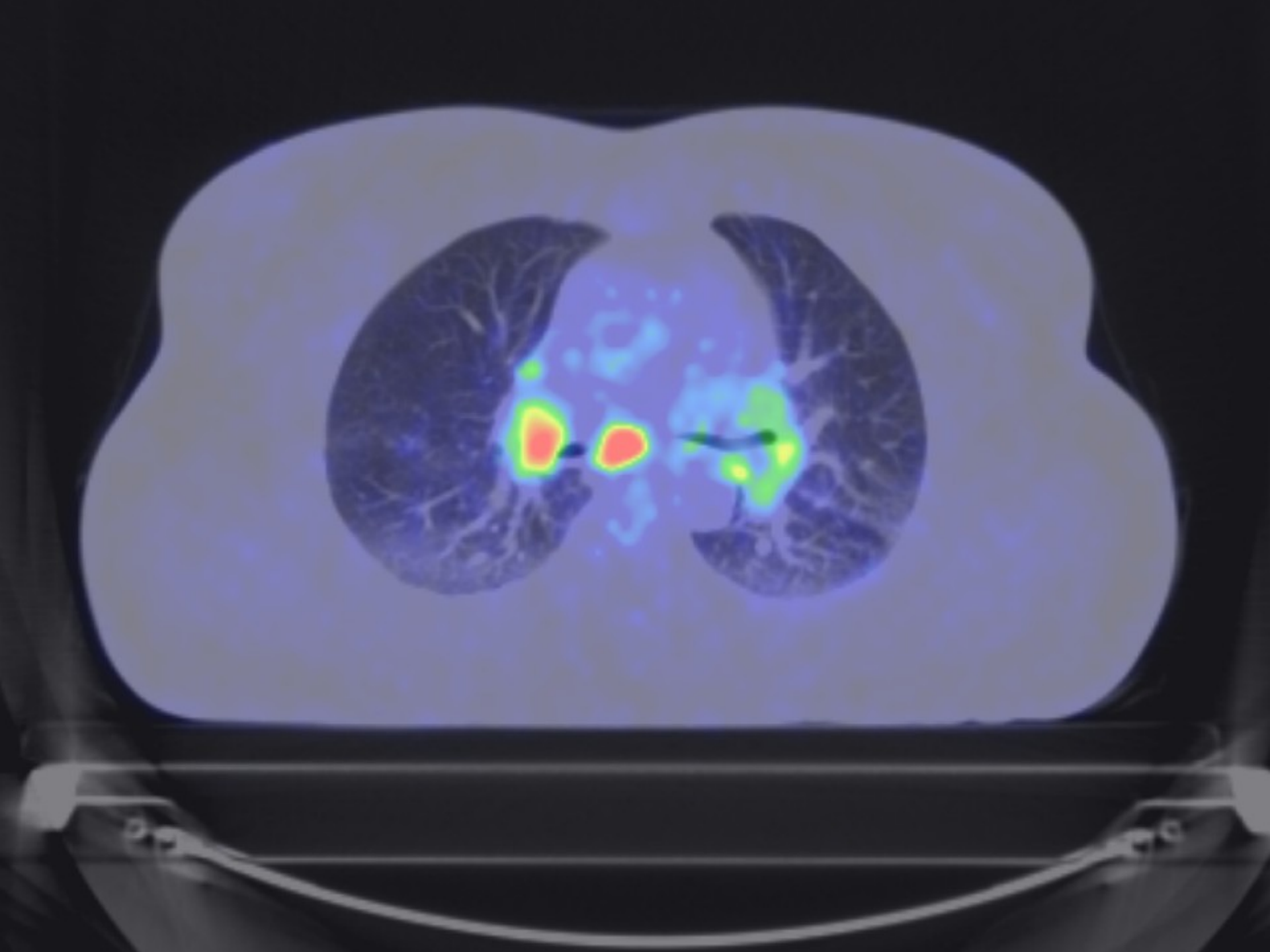
Volume

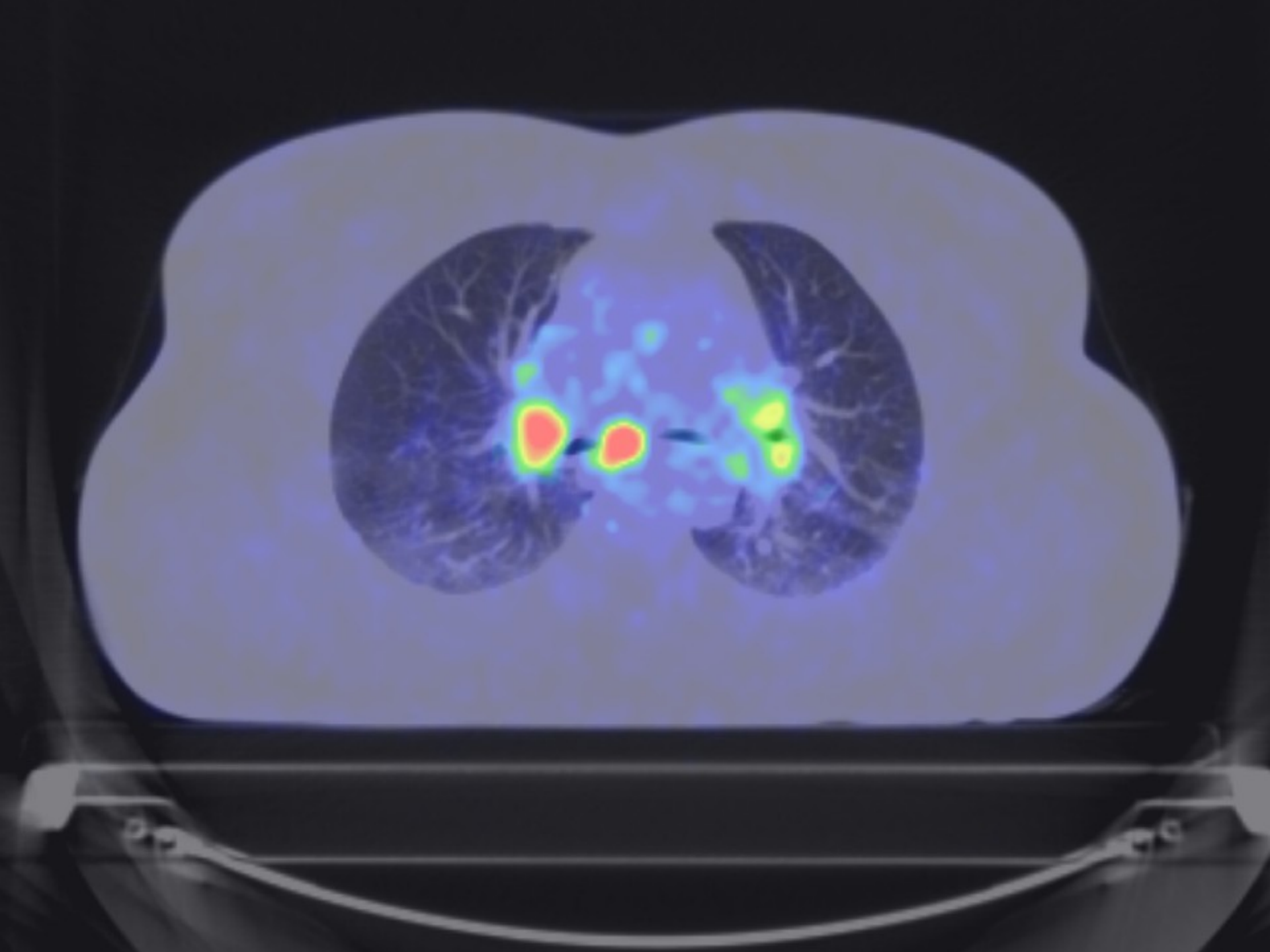
Referencing

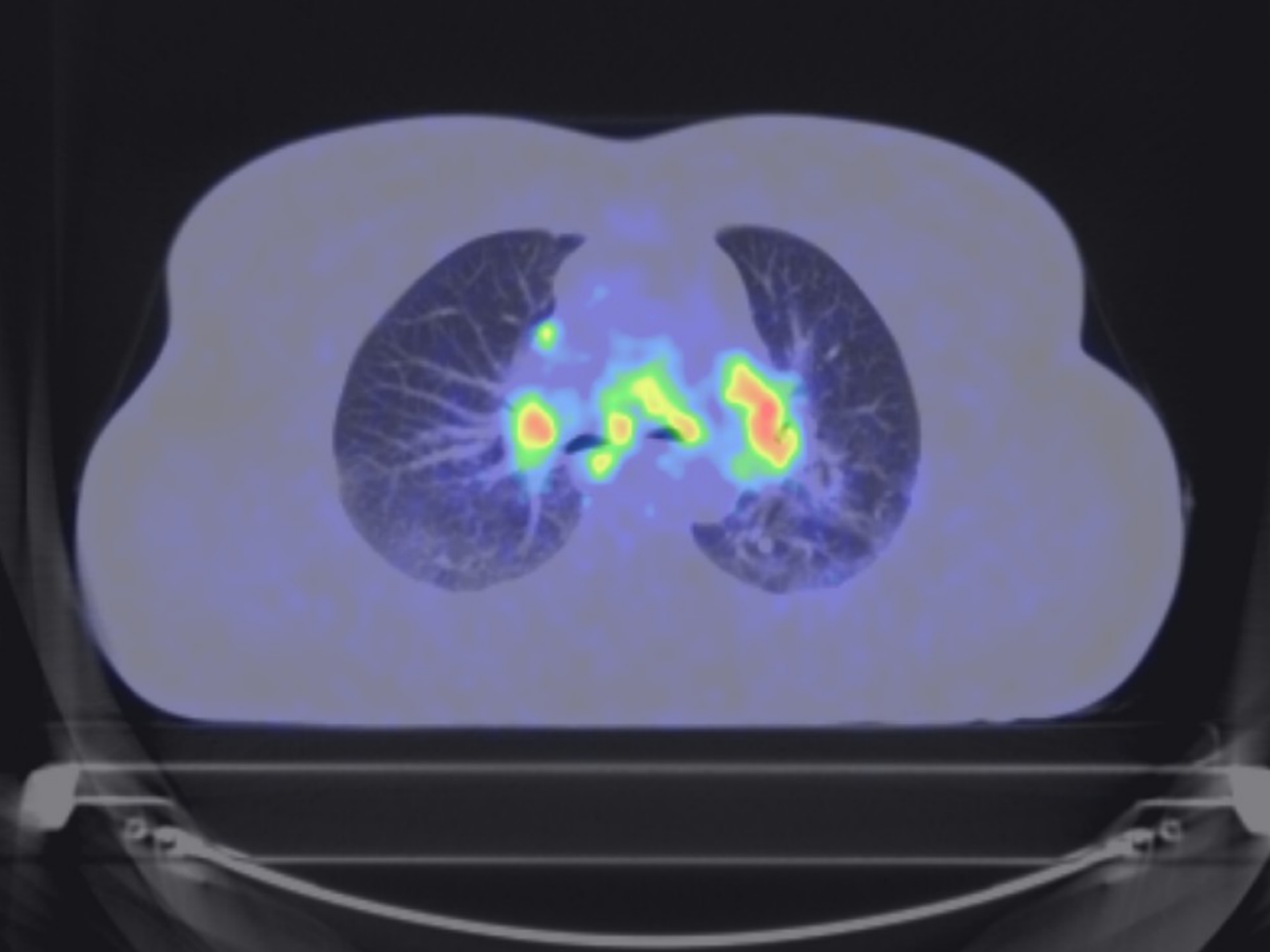
Flip

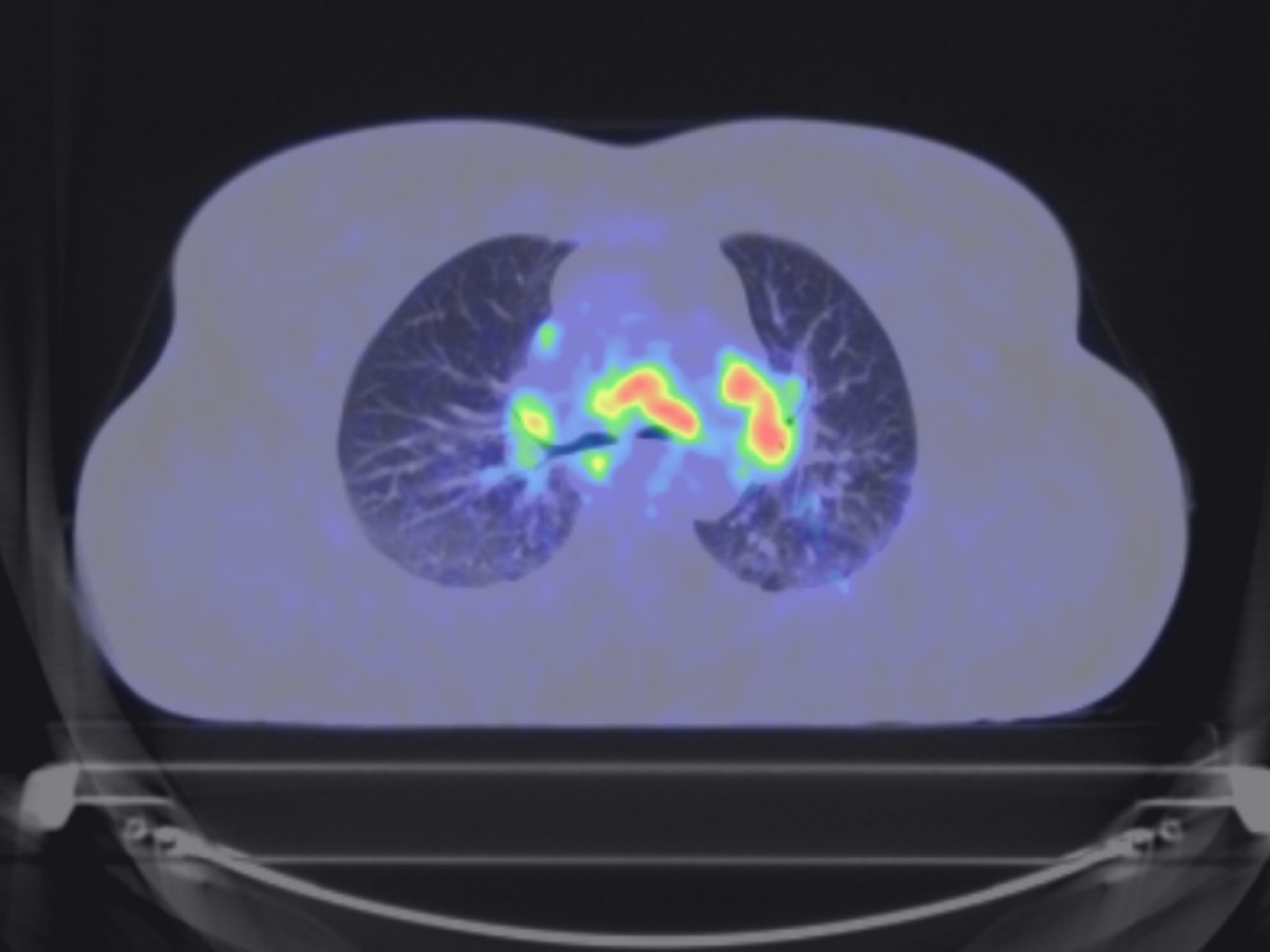
Selection



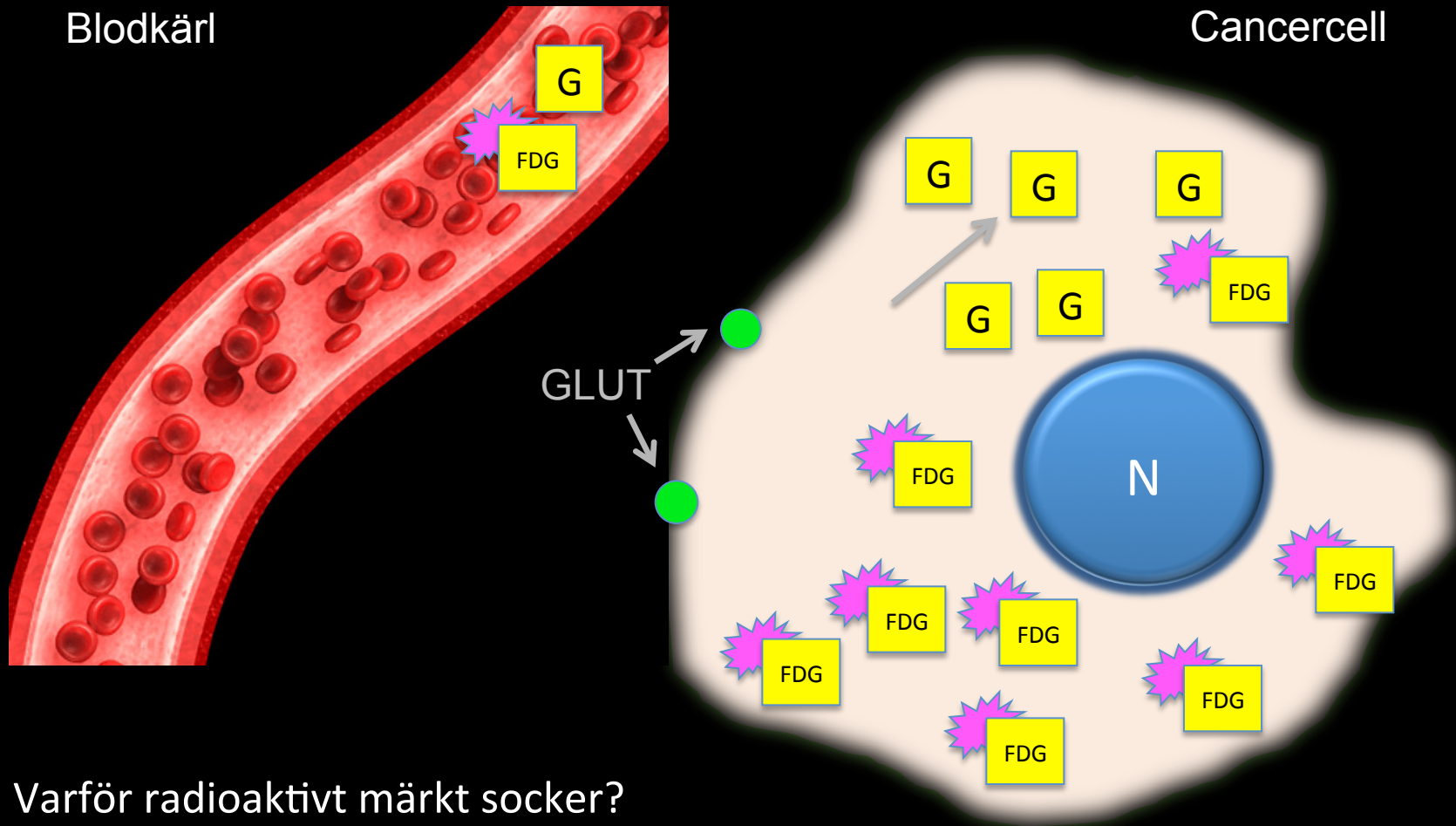








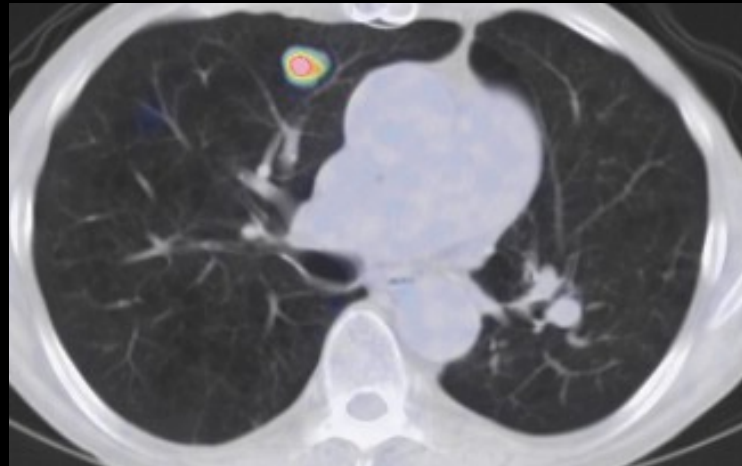
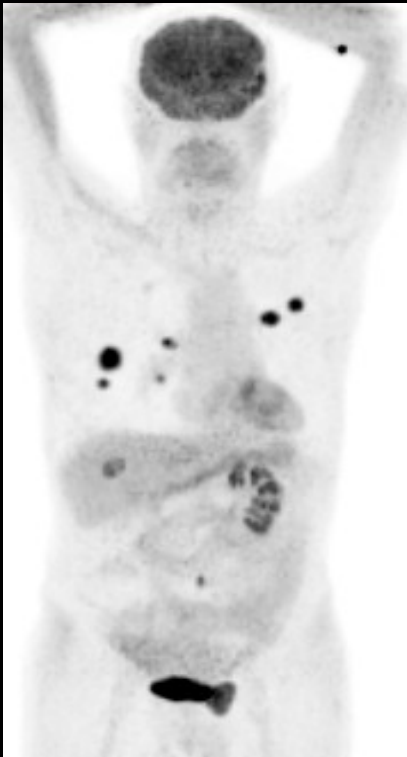
^{18}F -FDG-upptag i cancerceller



Varför radioaktivt märkt socker?
Ökad metabolism - ökat behov av snabb energi

Metoden PET-CT

- Kvalitativ och kvantitativ metod
 - Fysiologiskt/Patologiskt
 - Kvalitativ: Detektion och visuell bedömning
 - Kvantitativ: SUV , dynamiska parametrar





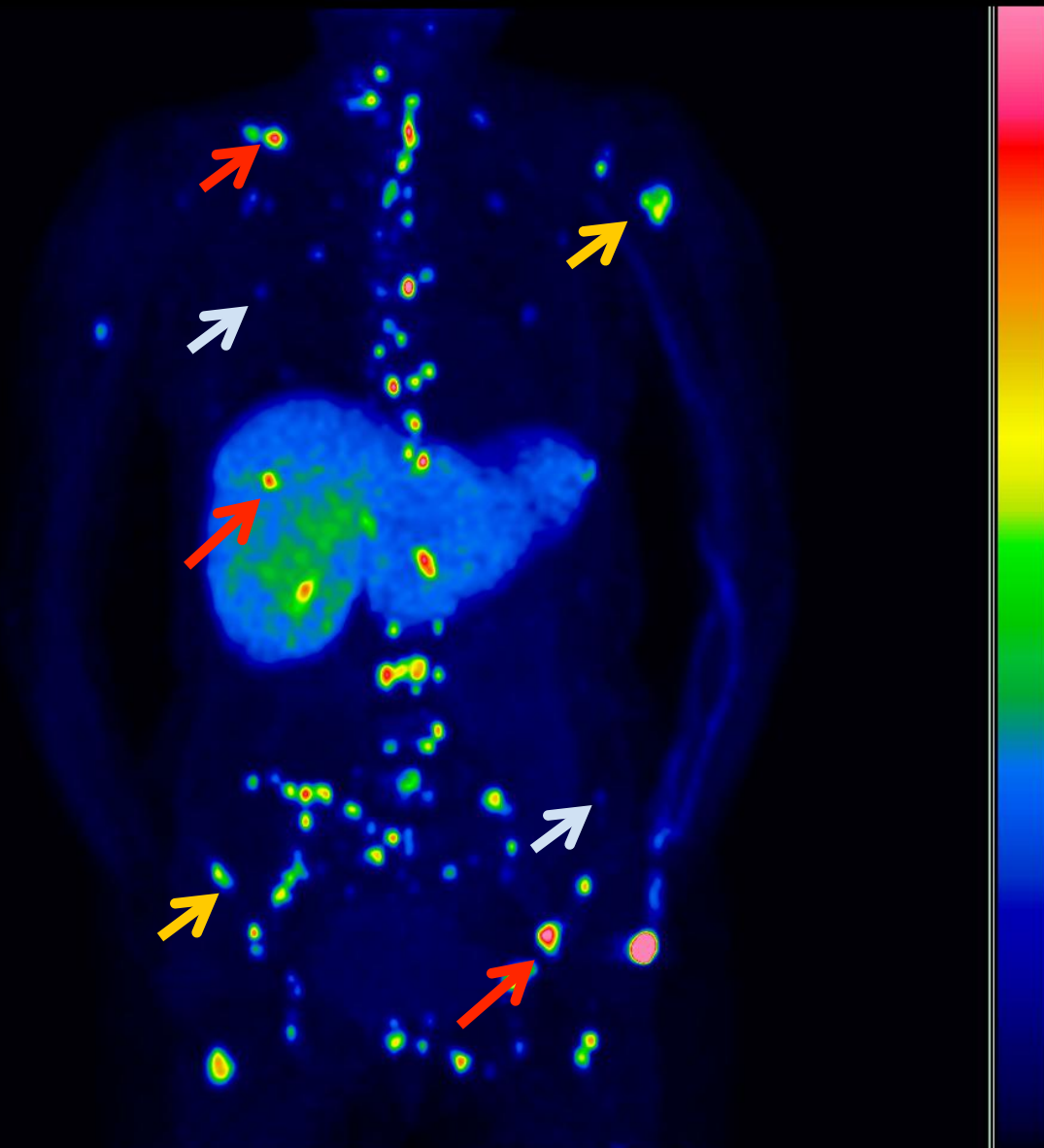
Intensivt



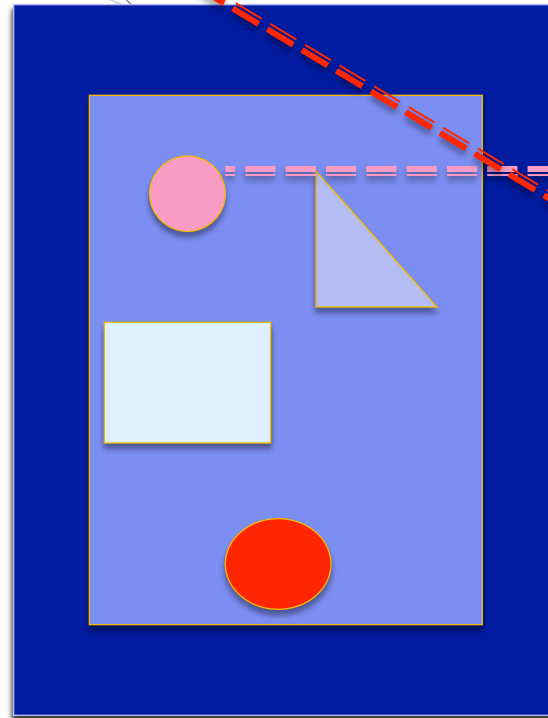
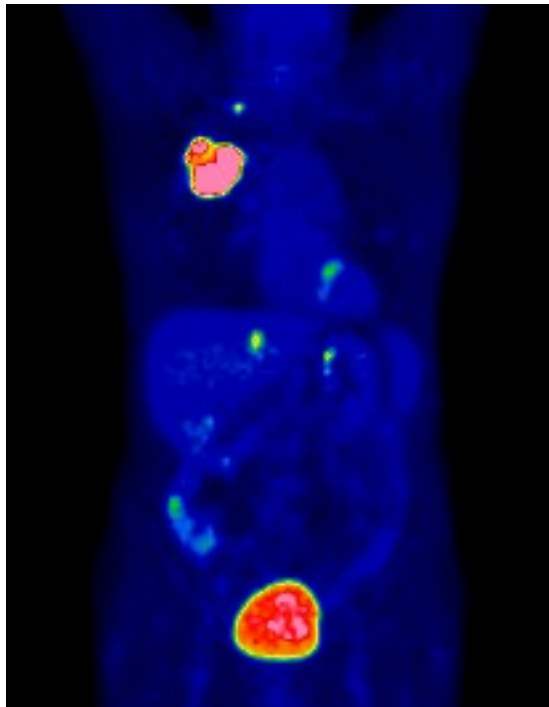
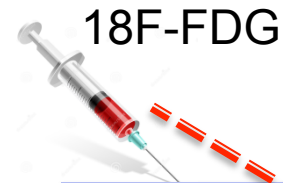Måttligt



Svagt



SUV: Standardized uptake value

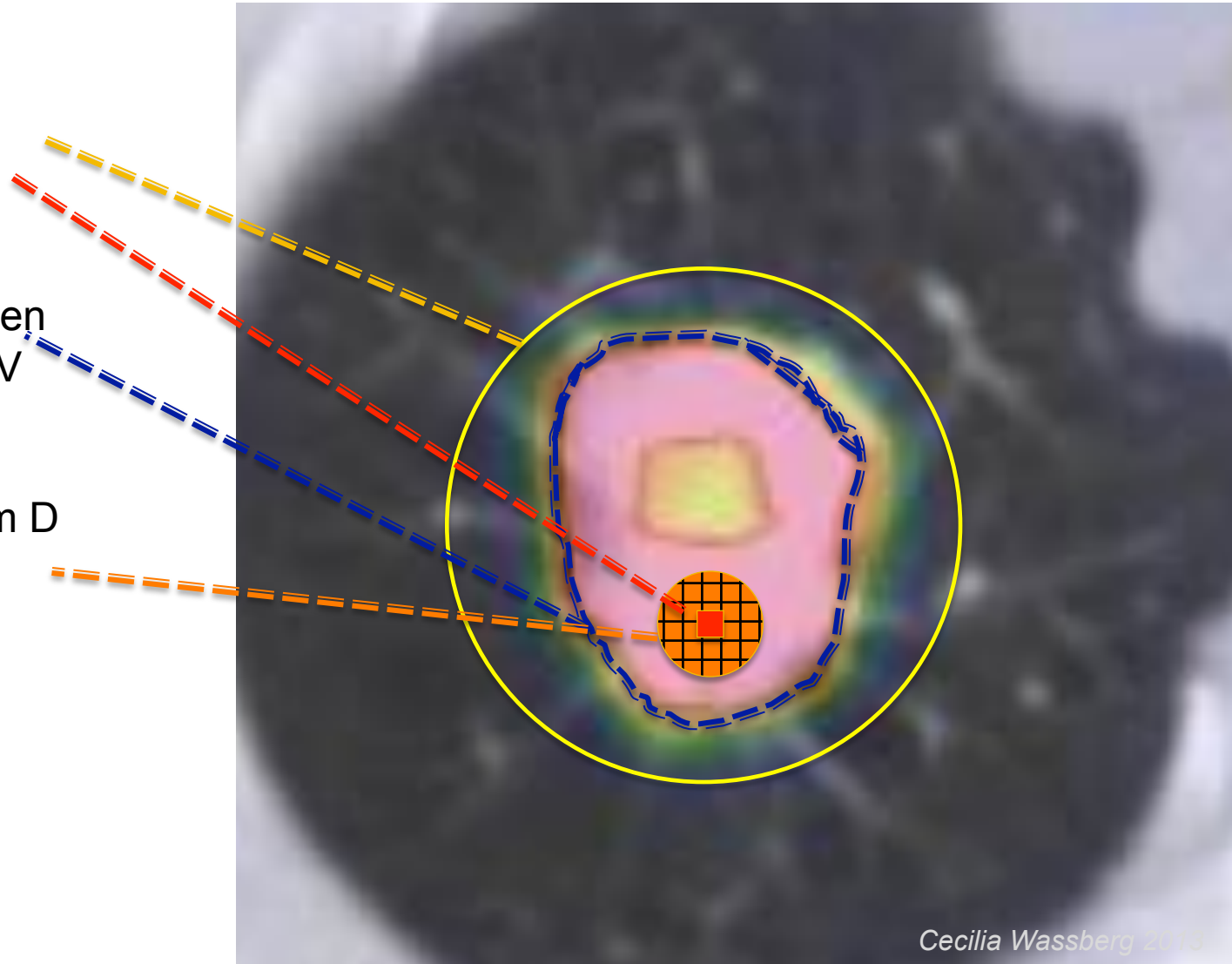


$$\text{SUV} = \frac{C}{\text{Injicerad dos} / \text{Kroppsvikt}}$$

kroppsvikt
lean body mass
body surface area

SUV: olika sätt att rapportera

- ROI/VOI
 - SUVmean
 - SUVmax
- Isocontouring
 - Tröskelvärden
 - 2,5 SUV
 - 50%
- VOI (sfär) 1,2 cm D
 - 1 cm³
 - SUVpeak



18F-FDG PET/CT och kliniska indikationer

	<u>Stadiumindelning</u>	<u>Behandlingsrespons</u>	<u>Recidiv</u>
Lunga	++++	+	+++
Lymfom	++++	++++	++
Malignt melanom	++	+	+++
Head- och Neck	++++	+	++
Kolorektal	+++		+++
Esofagus	++		++
Oklara primärtumörer	++++		
Gyn (cervix och ovarial)	+		+
Bröst	+++		++
Prostatacancer	Andra tracers		

Bakgrund - PET-DT och Lungcancer

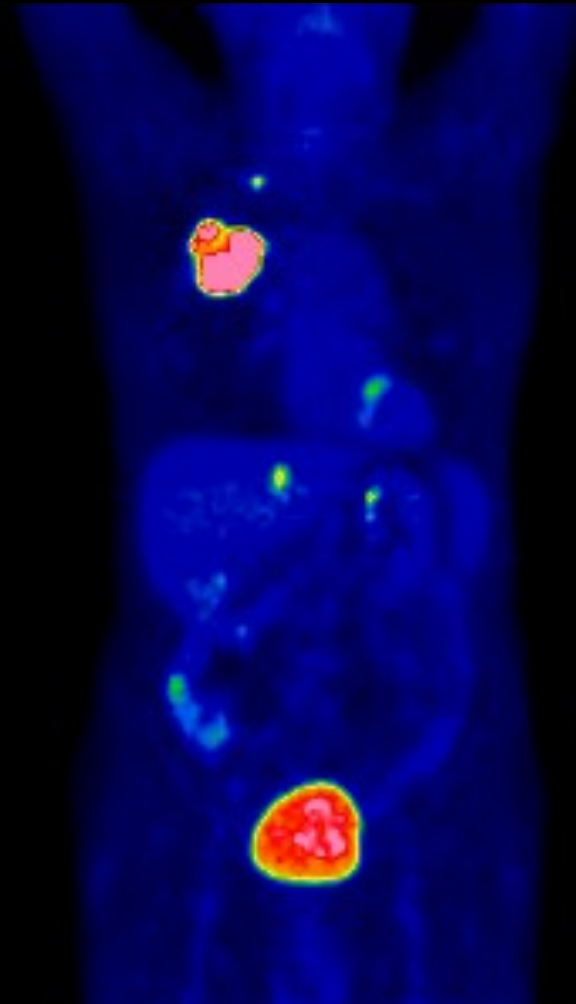
Nationella riktlinjer för
lungcancervård 2011
– stöd för styrning och ledning

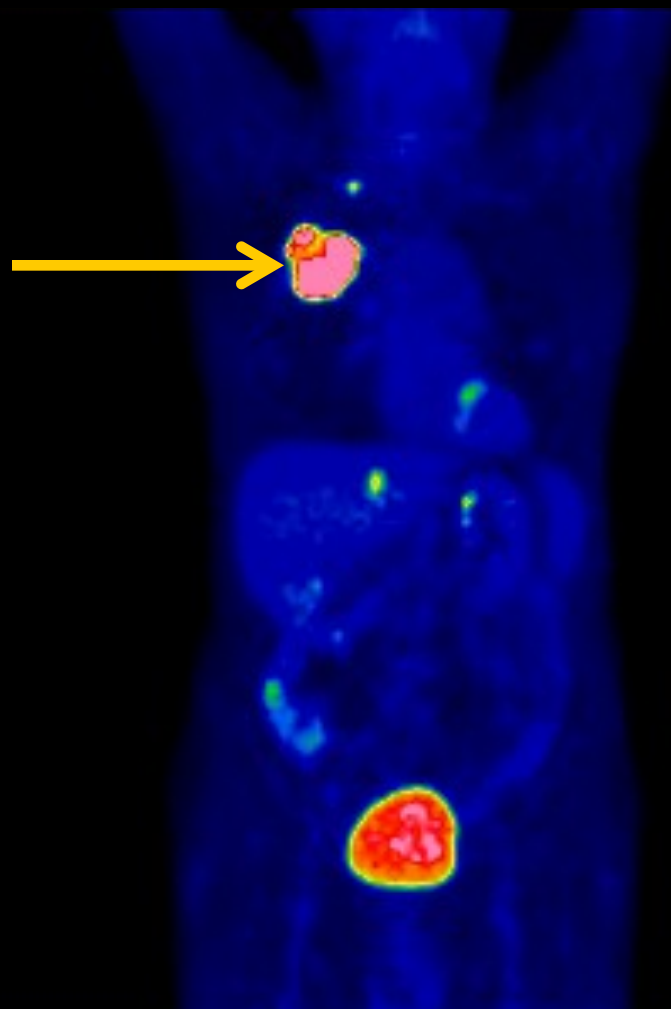
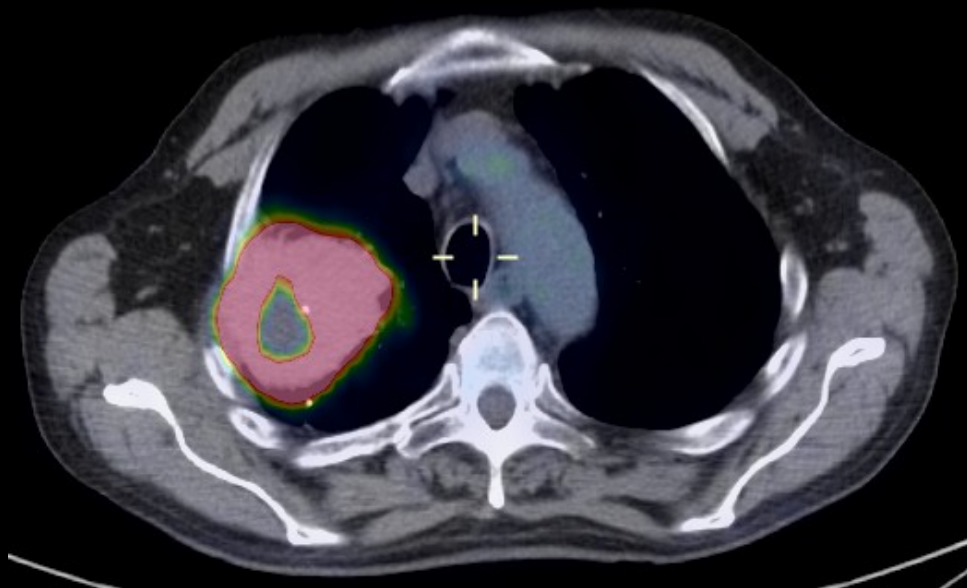
 Socialstyrelsen

- 2008 gjordes PET-DT på 21% (637 personer) av alla nydiagnostiserade fall av lungcancer
- Icke-småcellig lungcancer
- Behovet av PET-DT är sannolikt tre gånger så stort i utredningsfasen
- Varierade mellan de olika sjukvårdsregionerna (8-41%)

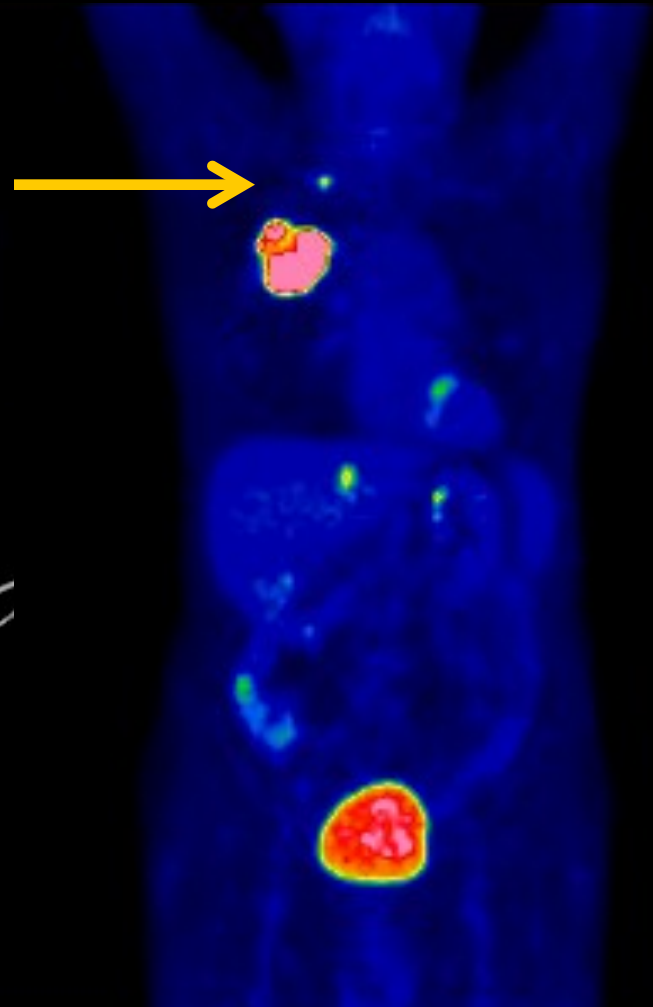
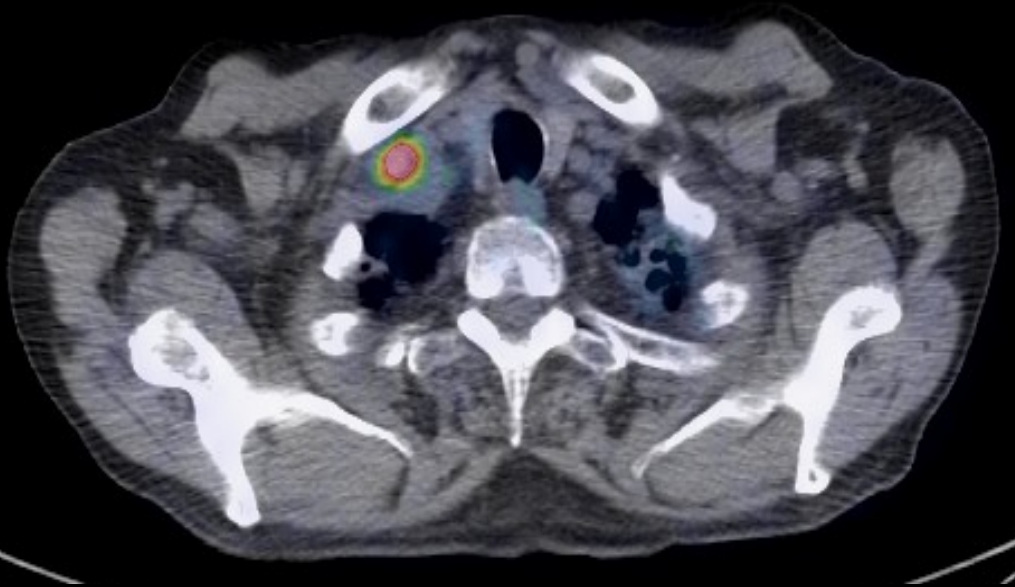
Tumörutbredning av icke-småcellig lungcancer

- Fall: 68-årig rökare. CT har visat en tumör i höger lunga.
- FDG PET/CT inför planerad kirurgi
 - Tecken på spridning?



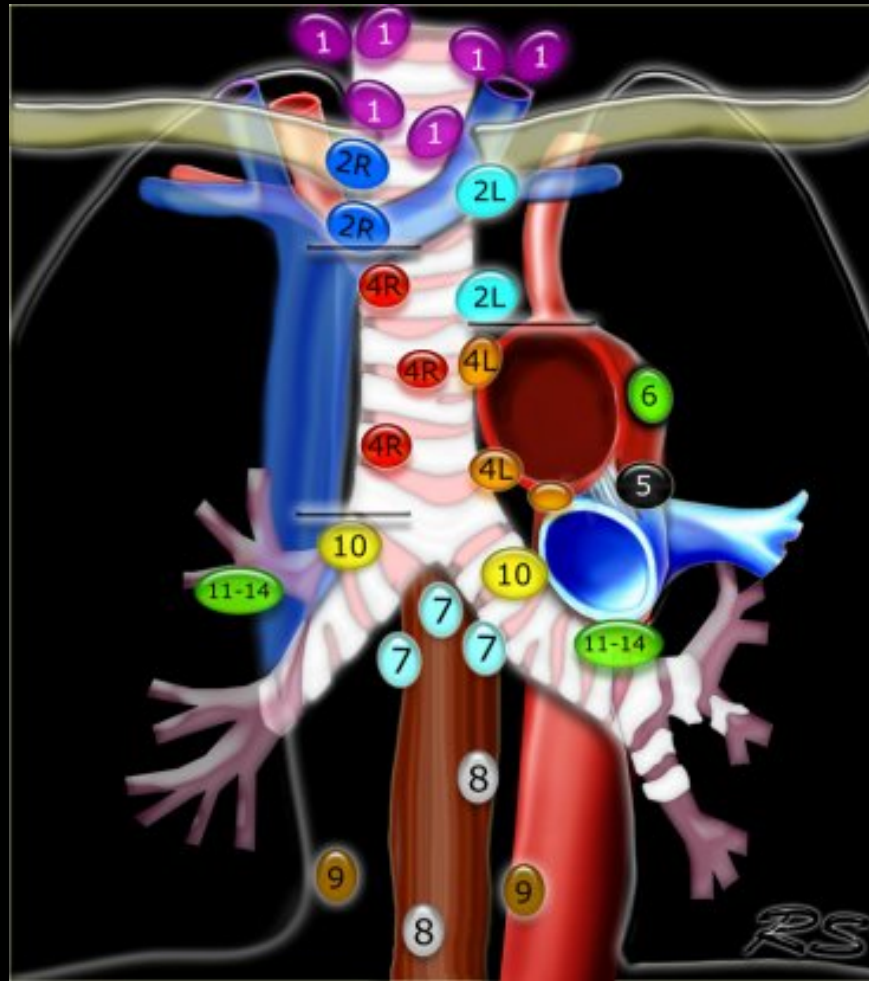


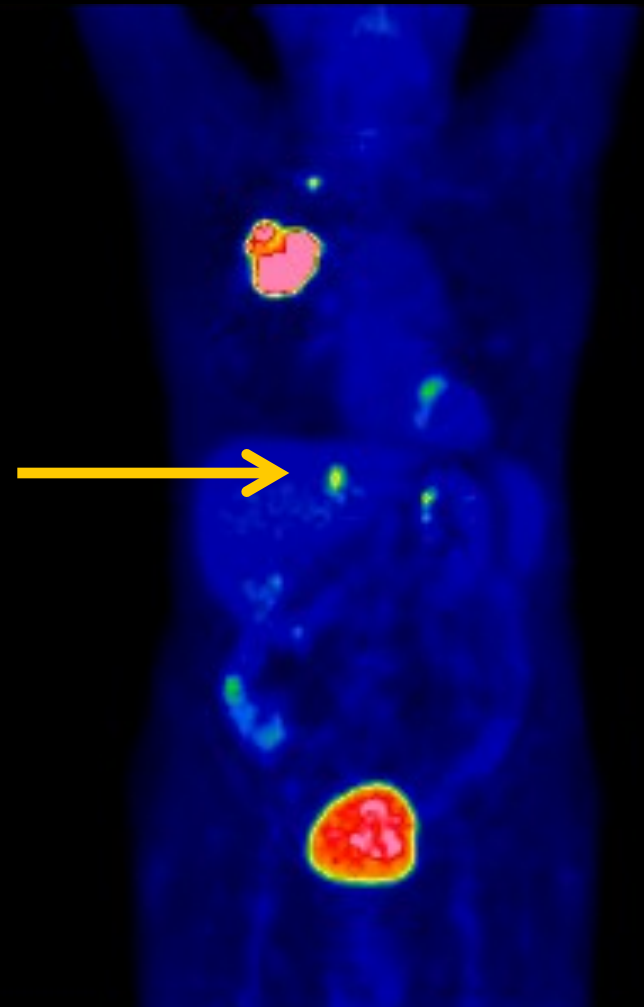
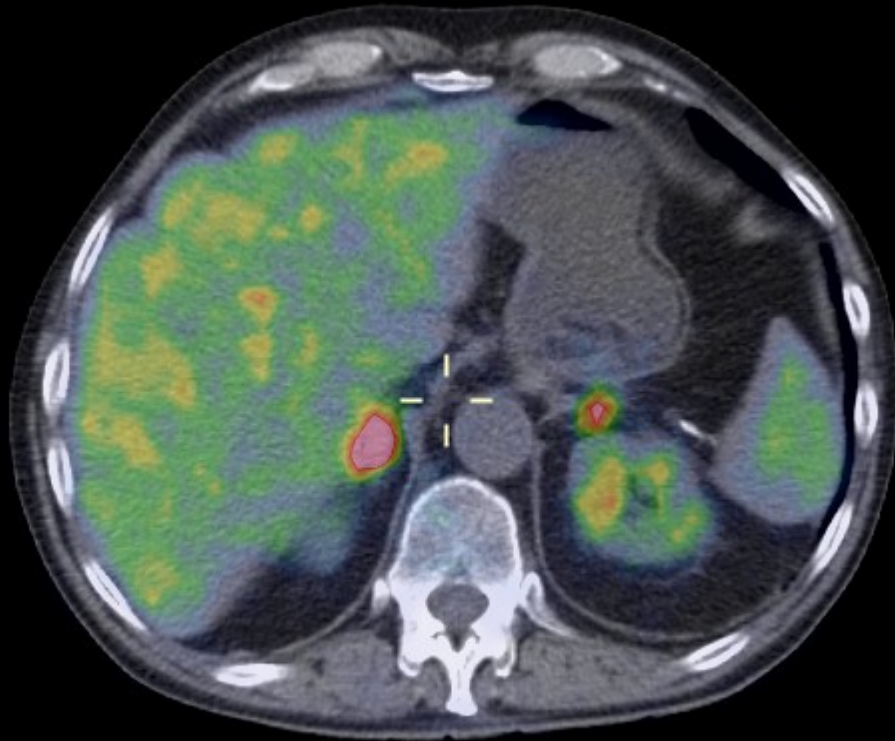
- Staging av Icke-småcellig lungcancer
 - T: Primärtumörens utbredning
 - N: Regional lymfkörtelutbredning
 - M : fjärrmetastasering



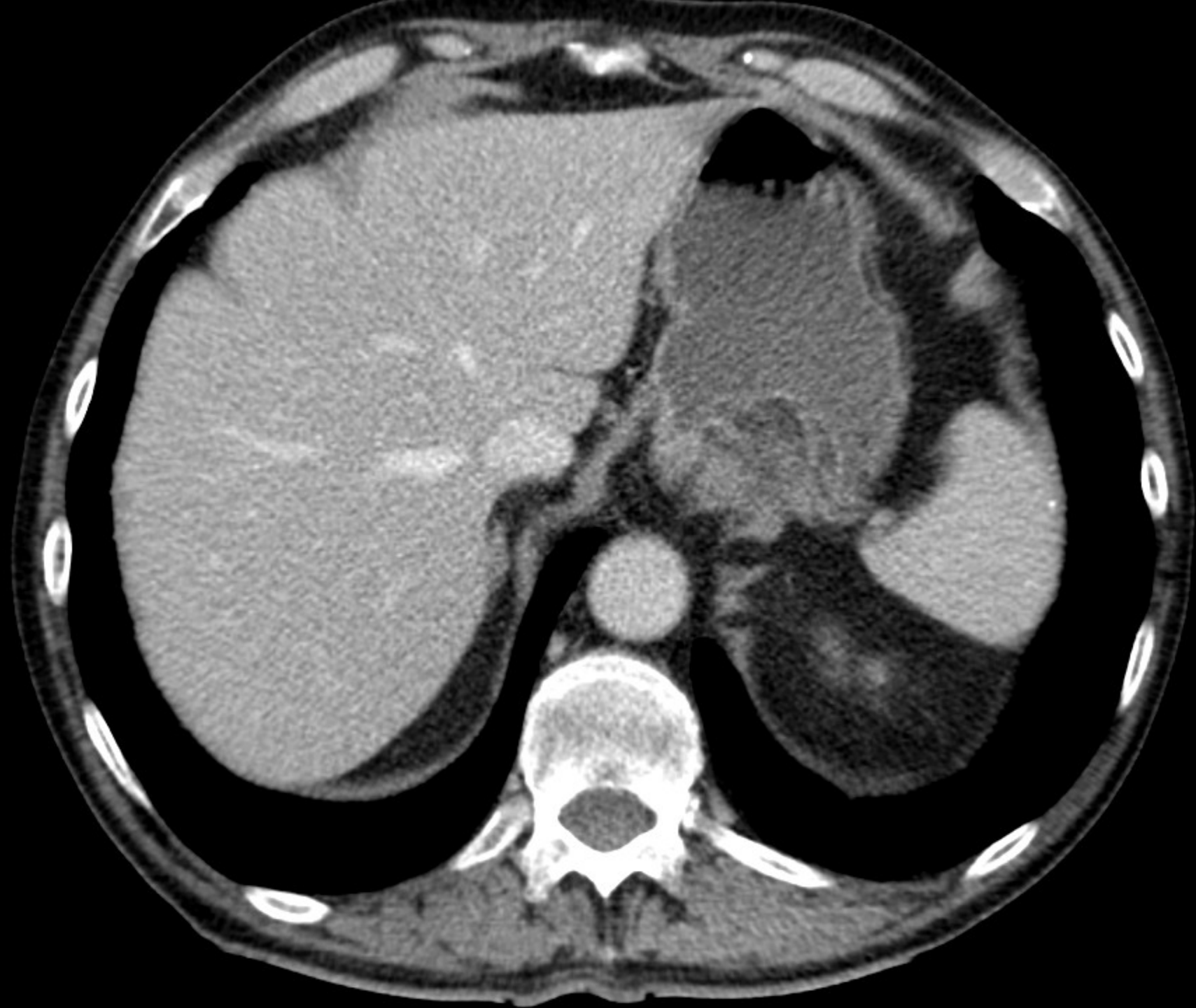
- Staging av Icke-småcellig lungcancer
 - T: Primärtumörens utbredning
 - N: Regional lymfkörtelutbredning
 - M : fjärrmetastasering

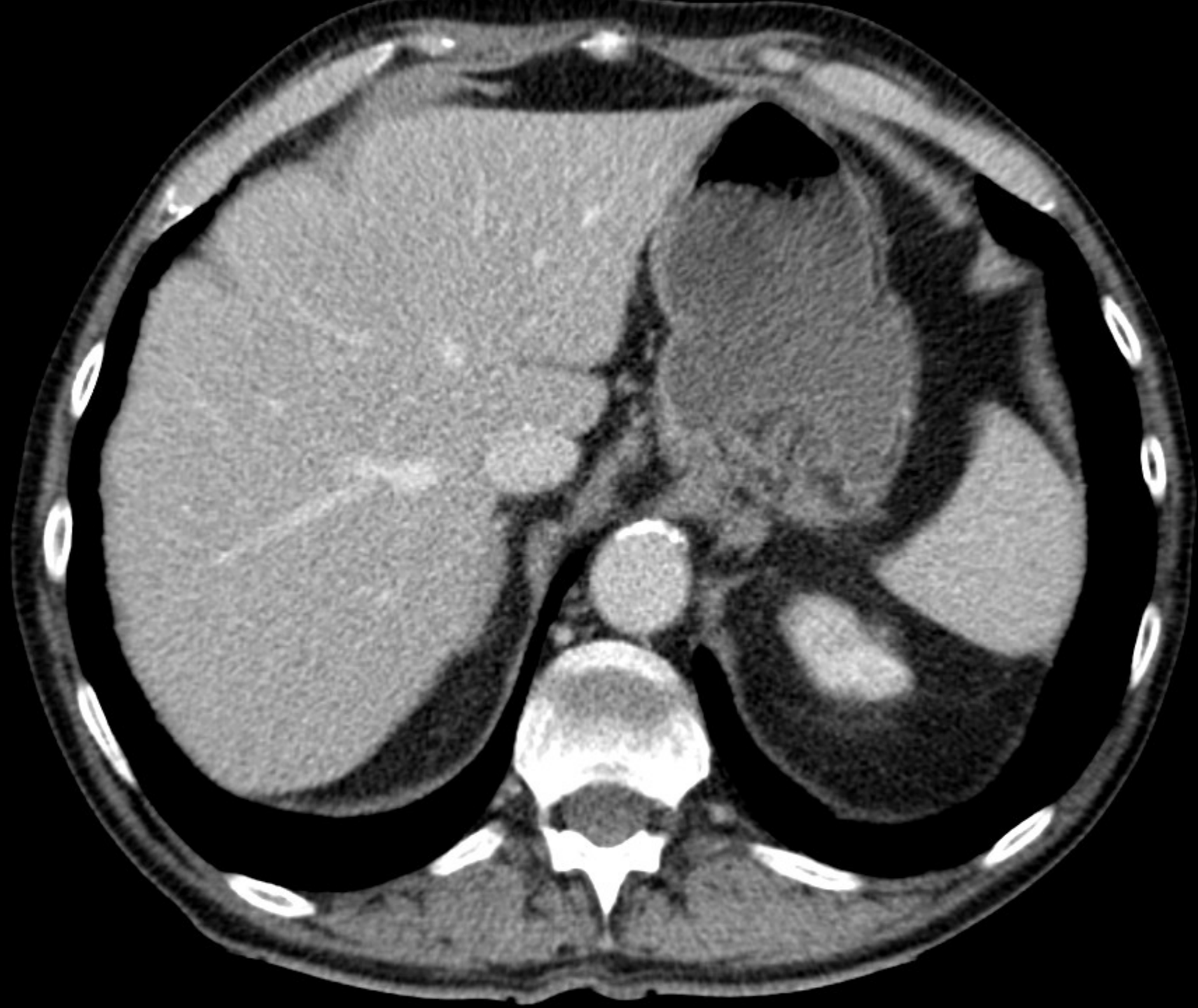
N-staging

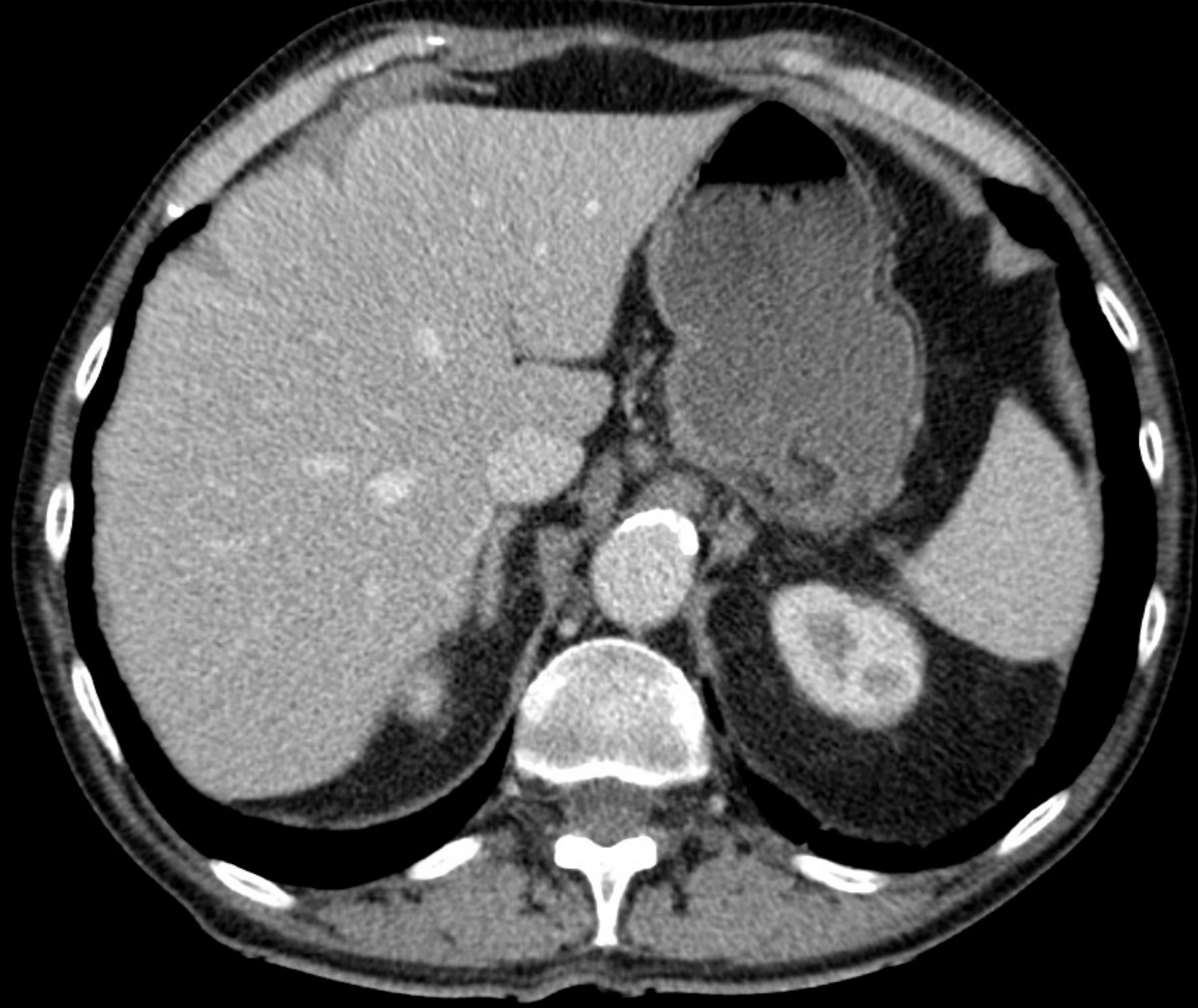


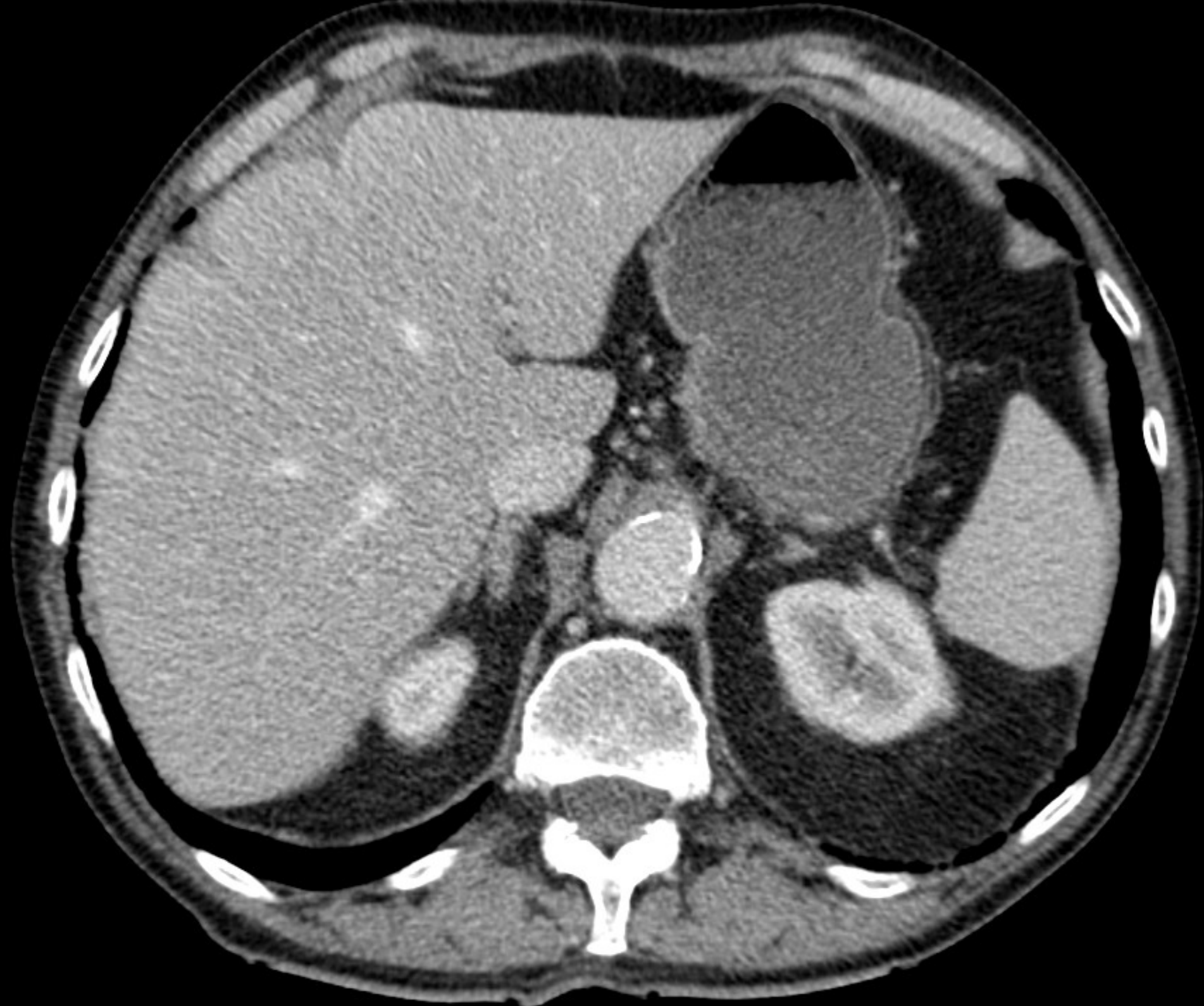


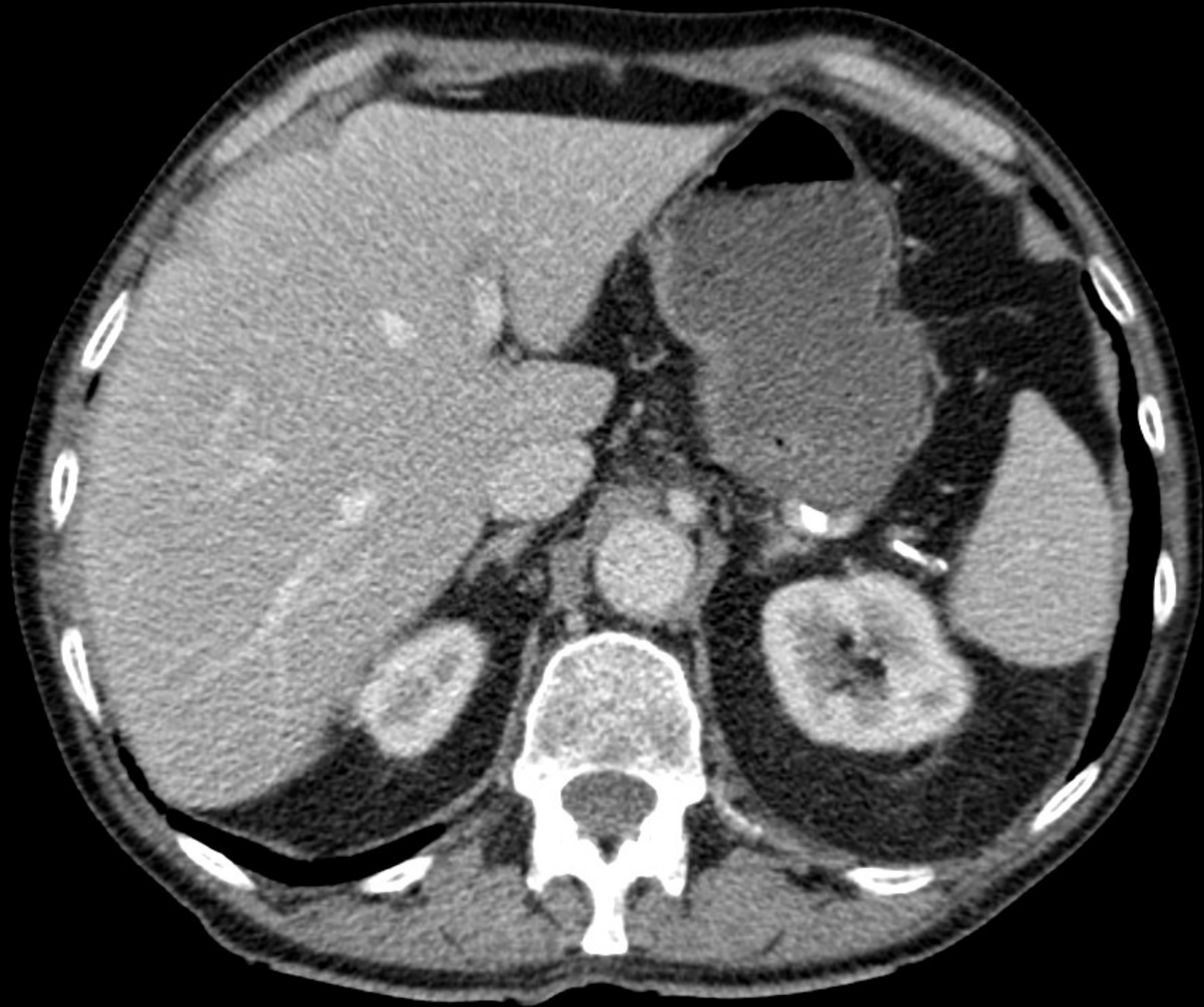
- Staging av Icke-småcellig lungcancer
 - T: Primärtumörens utbredning
 - N: Regional lymfkörtelutbredning
 - M : fjärrmetastasering

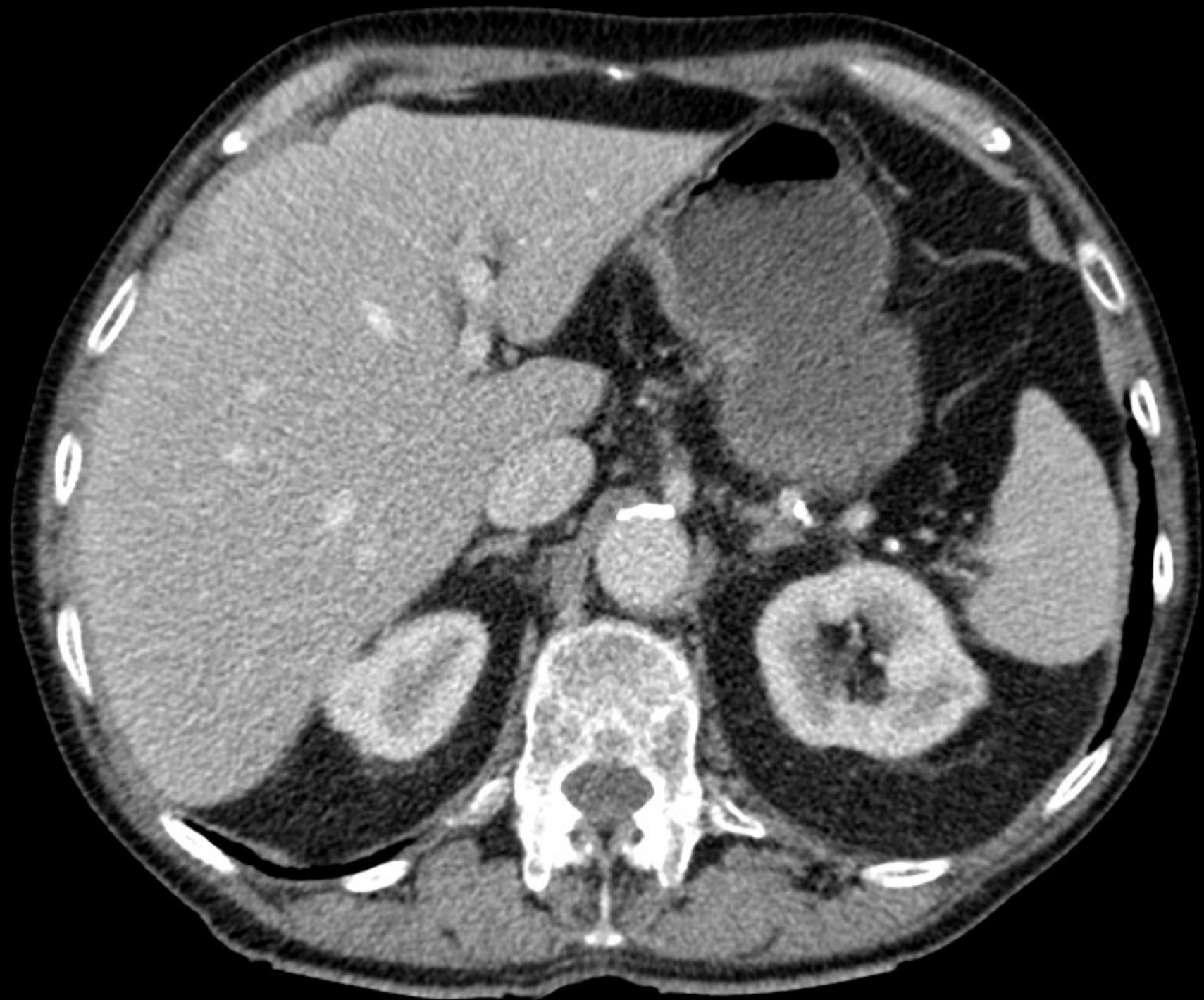


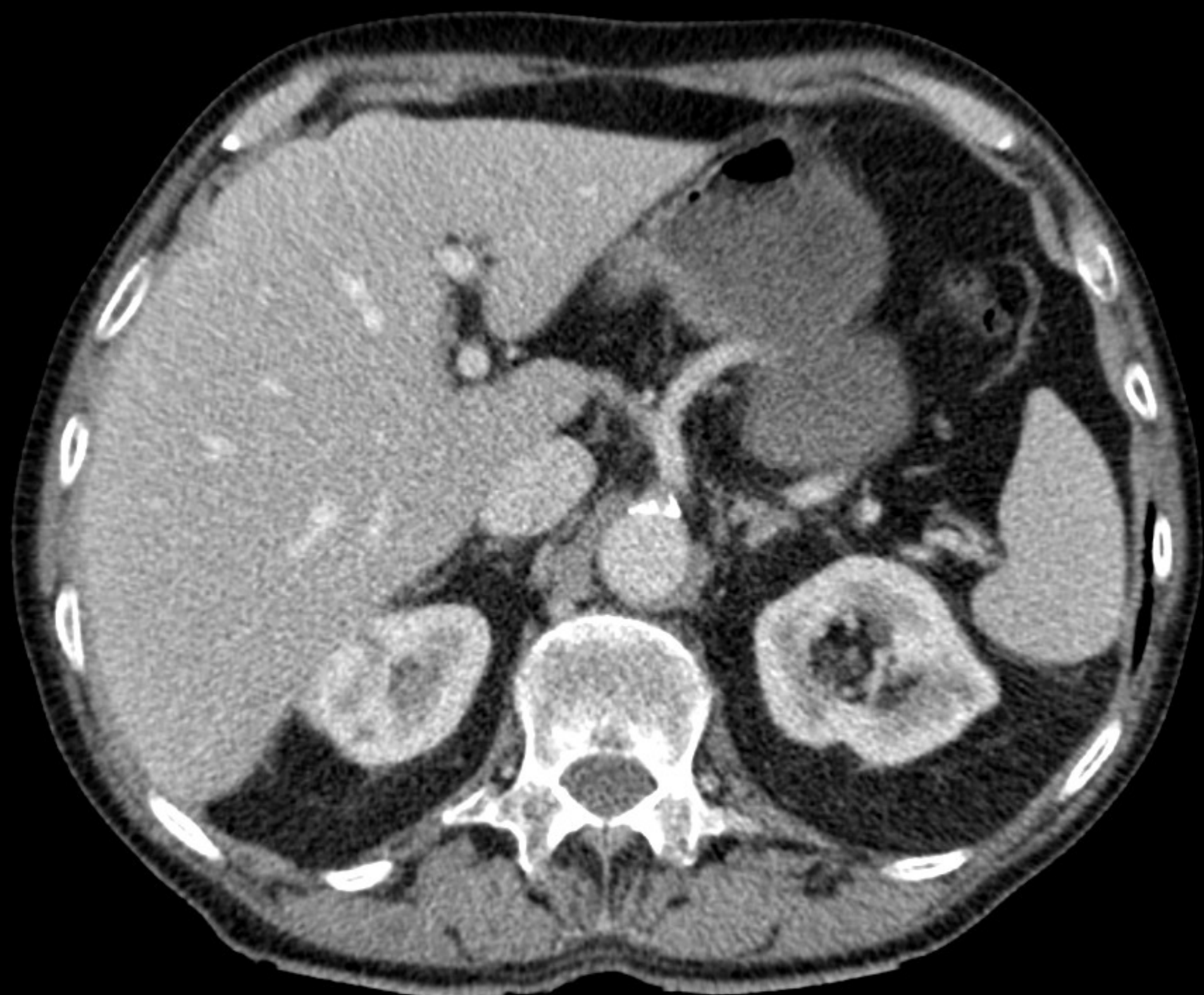

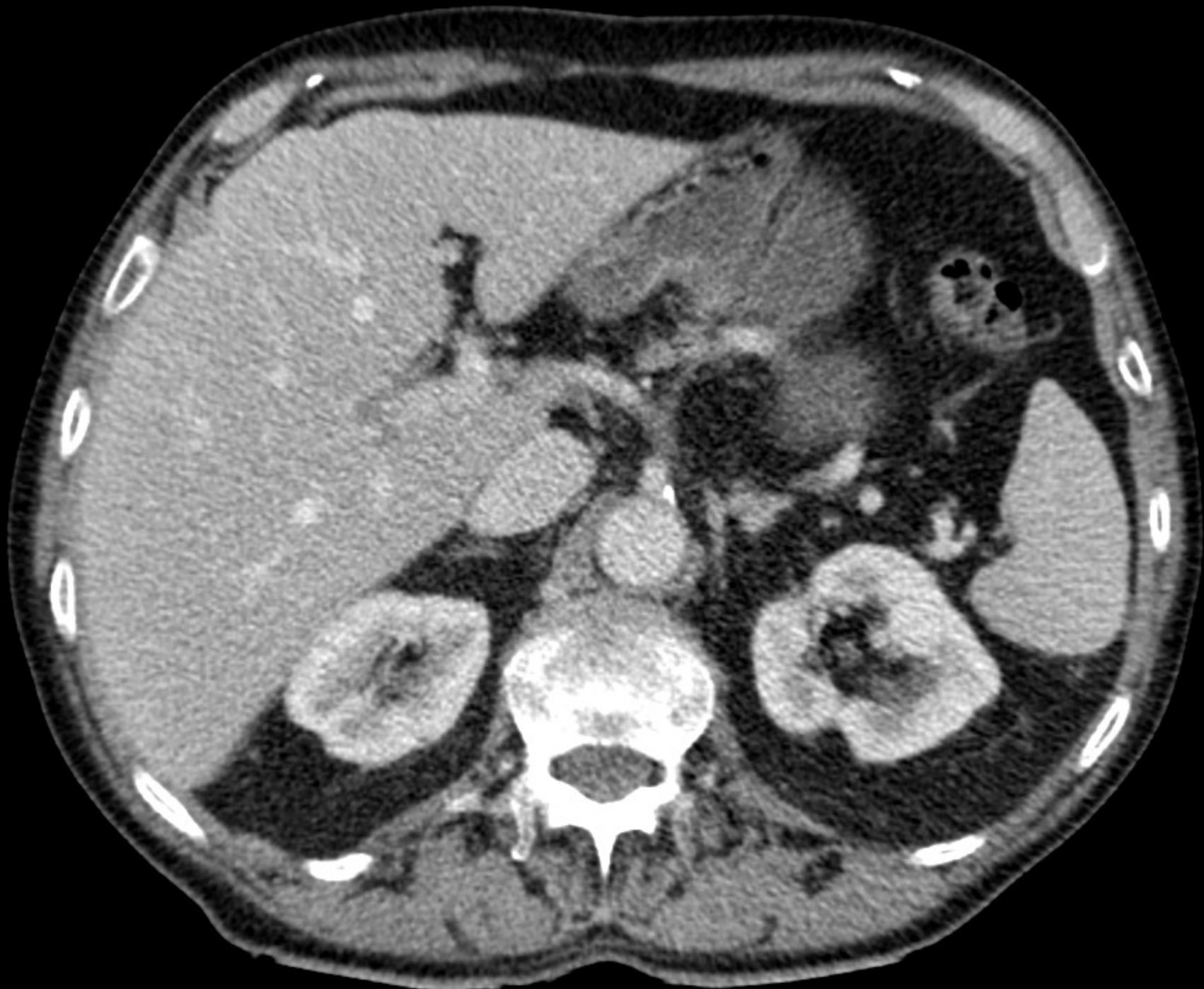


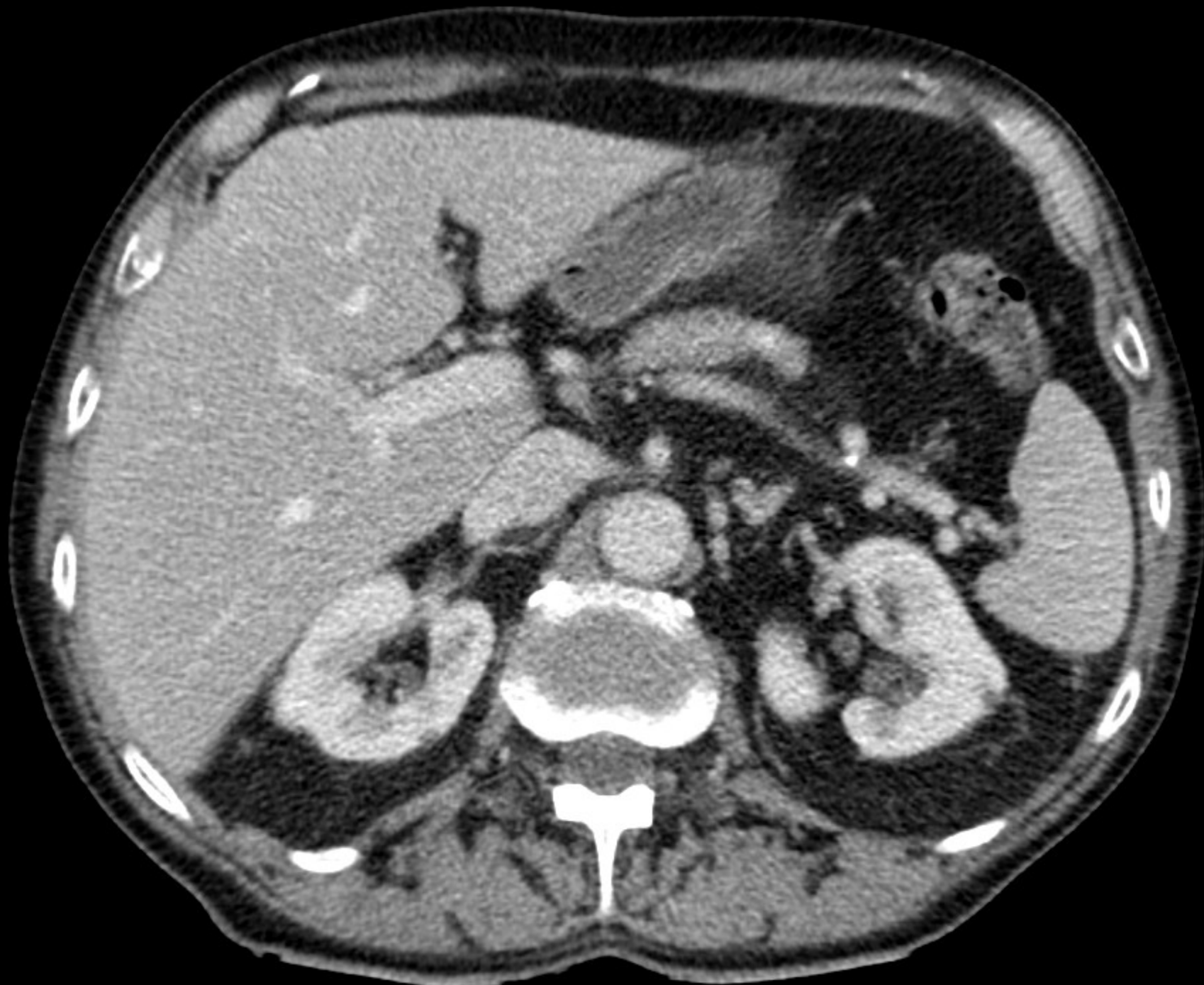


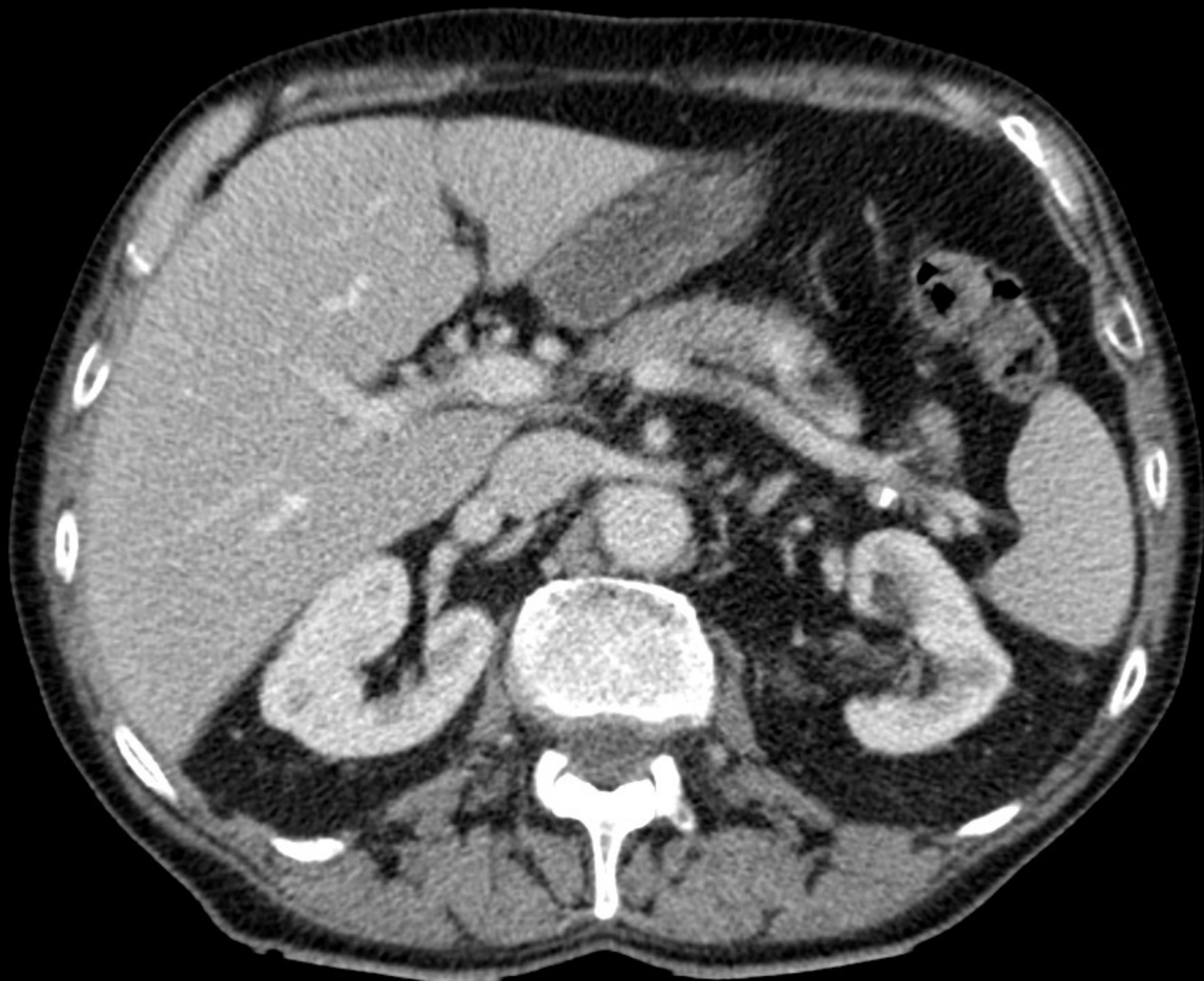



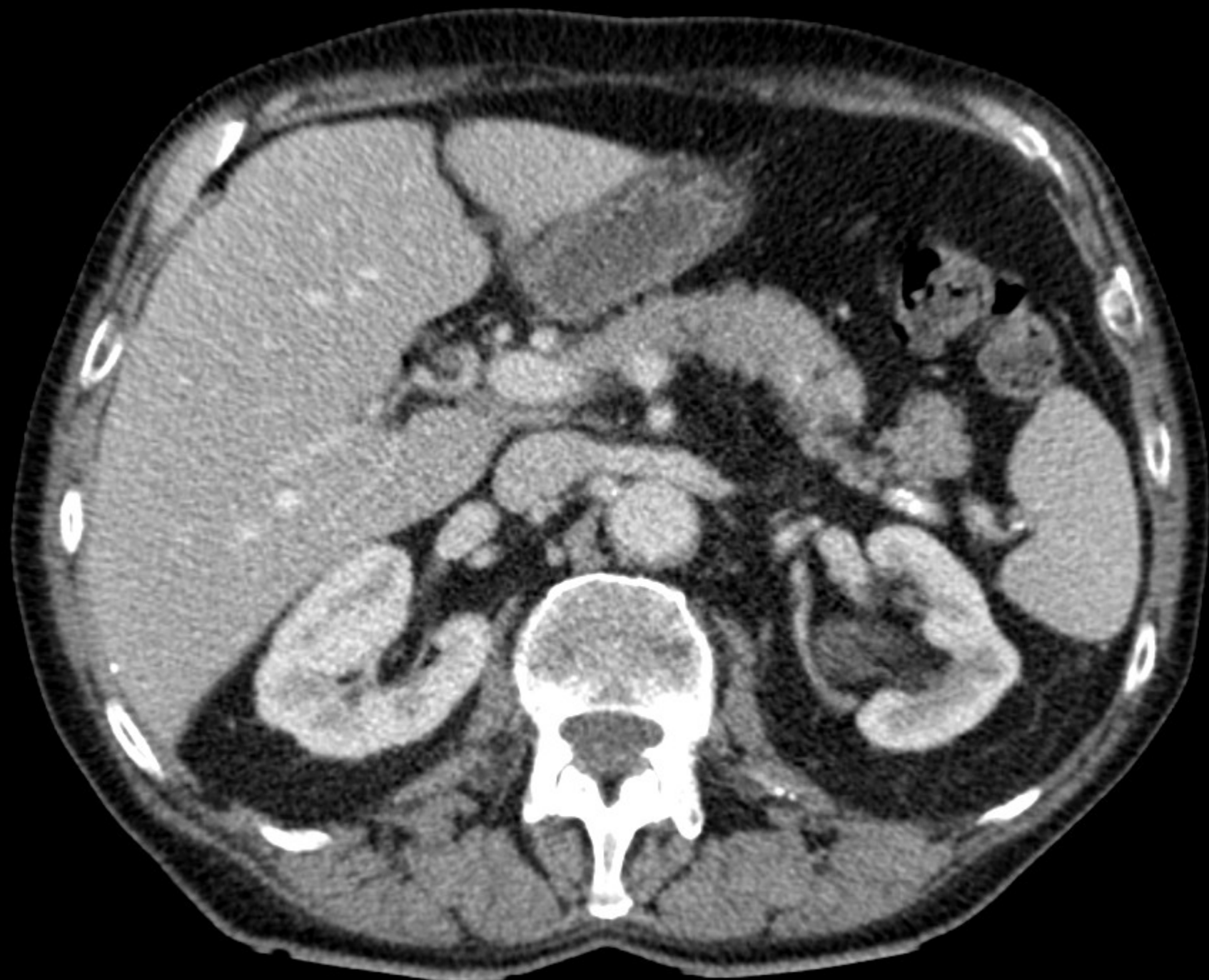
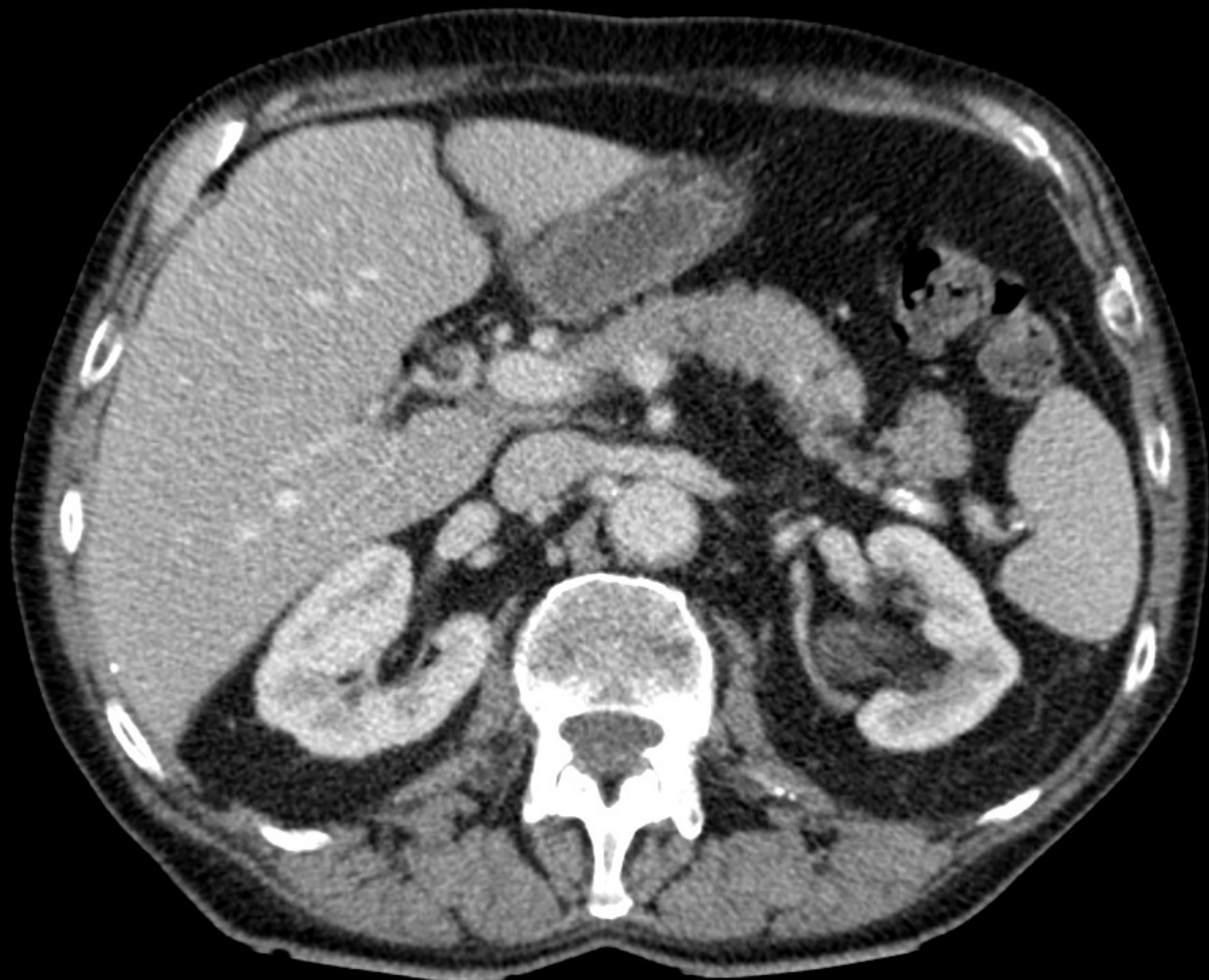












N och M-staging av NSCLC

- Mediastinala lymfkörtelmetastaser
 - Meta-analys
 - Sensitivitet CT 59% PET 83%
 - Specificitet CT 78% PET 92%
- Fjärrmetastaser
 - 10-20% påvisa fler fjärrmetastaser

Birim et al, Ann Thorac Surg,
2005;79:375-382, Fletcher et al JNM:
49:480-508, 2008,

PET-DT inför kurativ behandling

Nationella riktlinjer för
lungcancervård 2011
– stöd för styrning och ledning

Rekommendation om kartläggning av lungcancer inför kurativ behandling

Hälso- och sjukvården bör genomföra

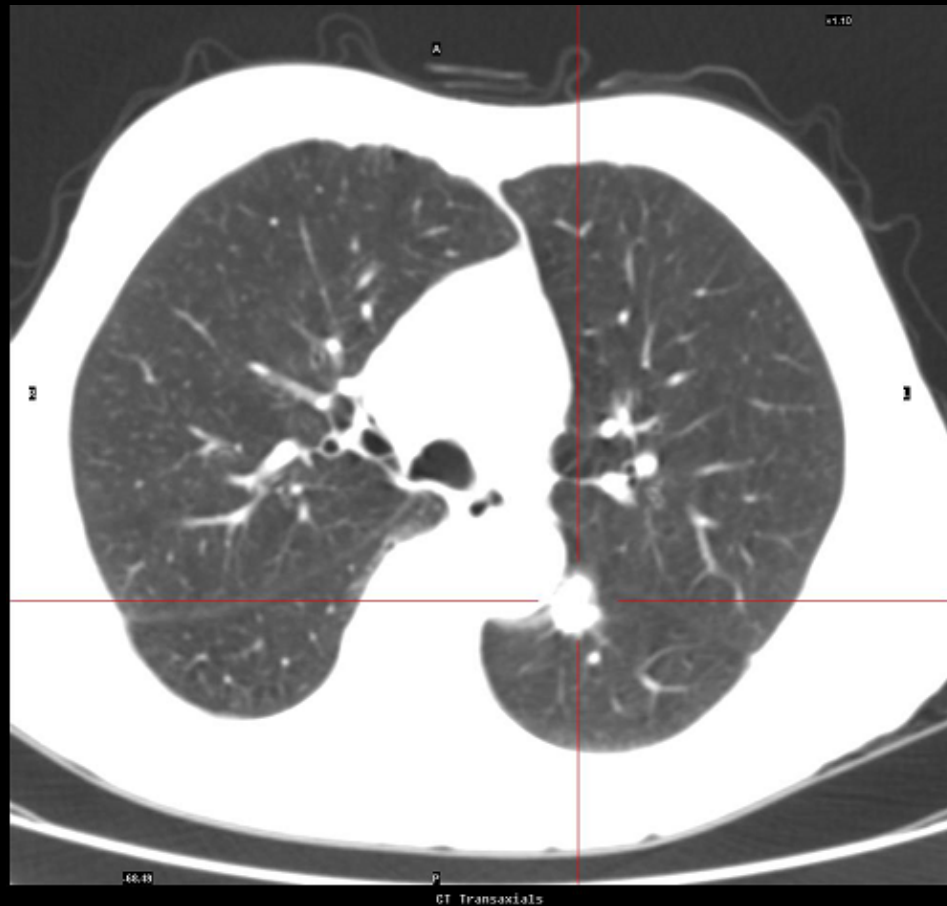- PET-DT (*prioritet 2*) för att hitta metastaser till mediastinum och fjärrmetastaser (*prioritet 3*) på personer med icke småcellig lungcancer

1	2	3	4	5	6	7	8	9	10	Icke-göra	FoU
---	---	---	---	---	---	---	---	---	----	-----------	-----

1	2	3	4	5	6	7	8	9	10	Icke-göra	FoU
---	---	---	---	---	---	---	---	---	----	-----------	-----

Rundhård - Solitary Pulmonary Nodule

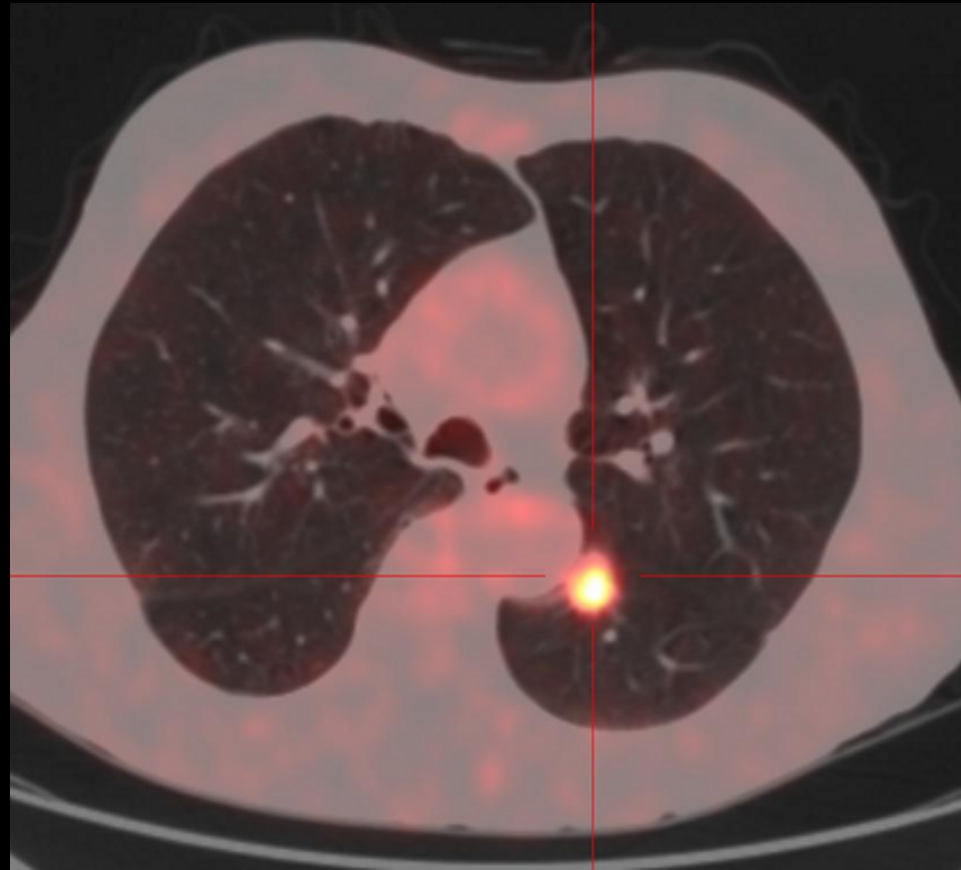
- Fall: M 64 år
 - Rökare
 - CT: 2,0 cm
- Malignitet?



Rundhård - Solitary Pulmonary Nodule

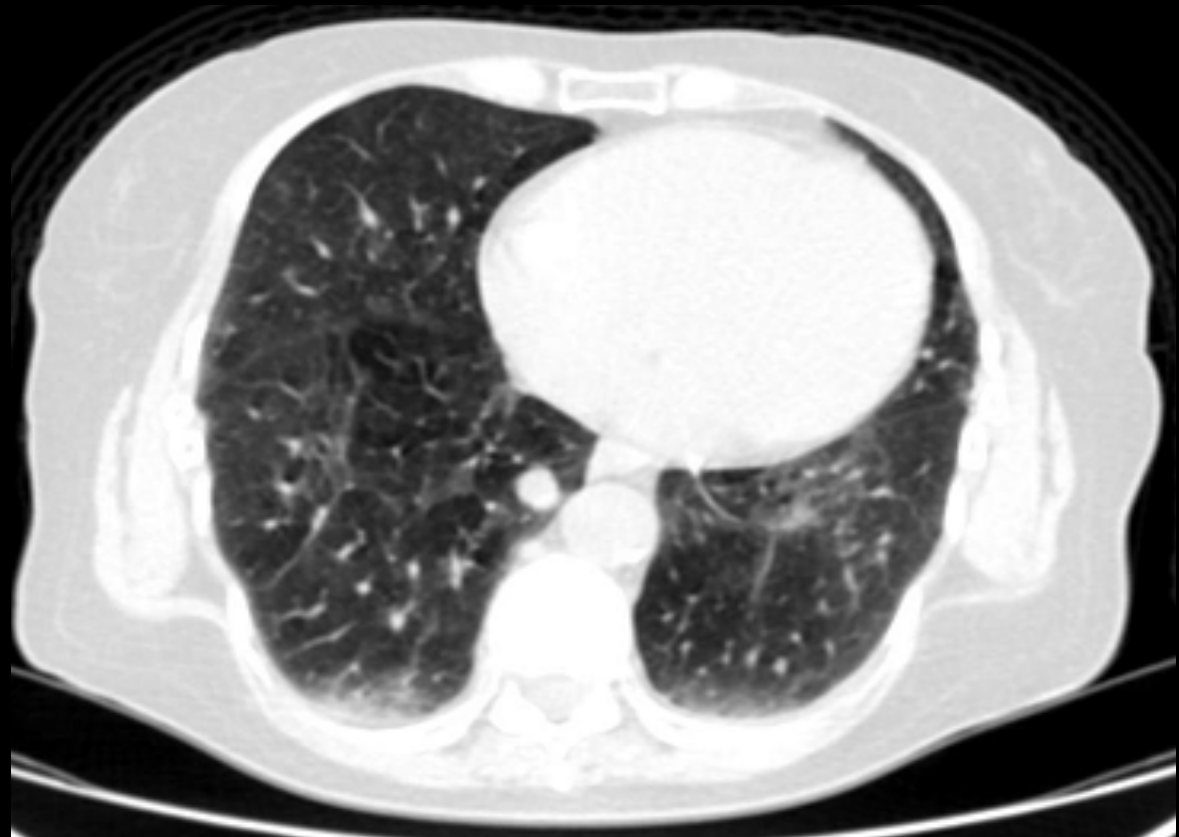- M 64 år
 - Rökare
 - CT: 2,0 cm
- Malignitet?

$SUV_{max} = 7$



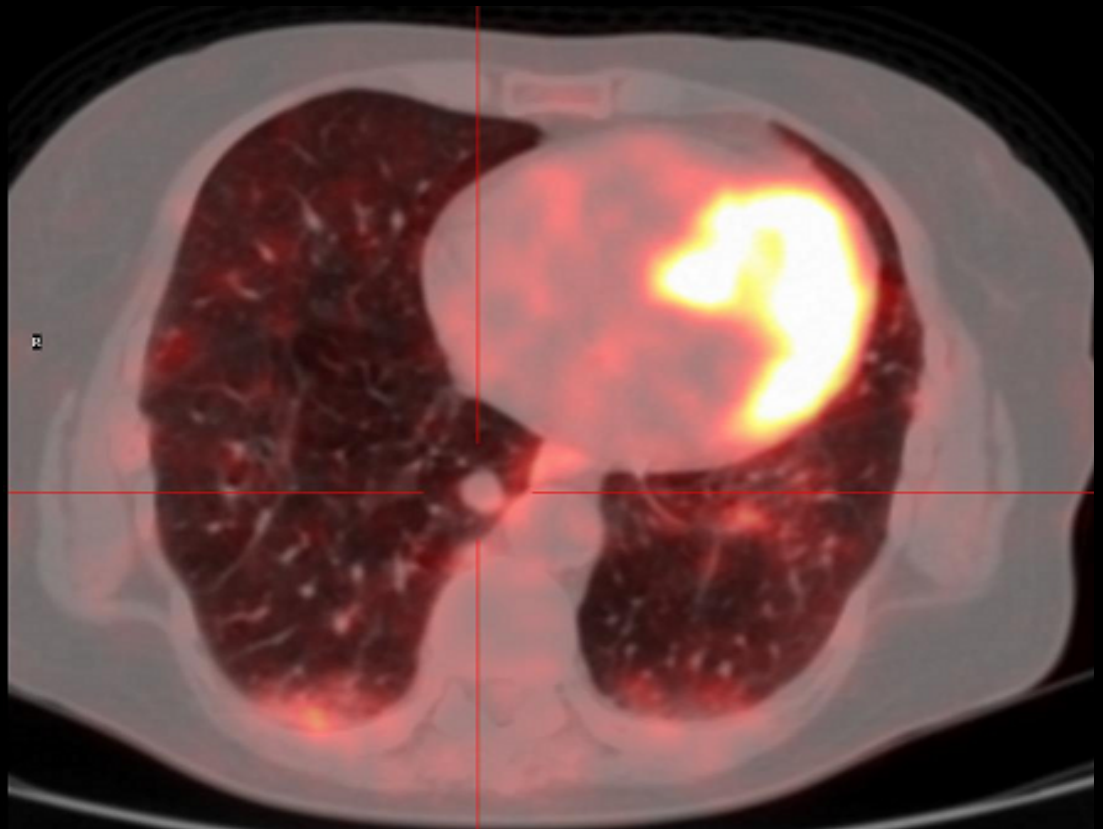
Rundhård - Solitary Pulmonary Nodule

- K 64 år
 - Rökare
 - CT: 1,5 cm
- Malignitet?

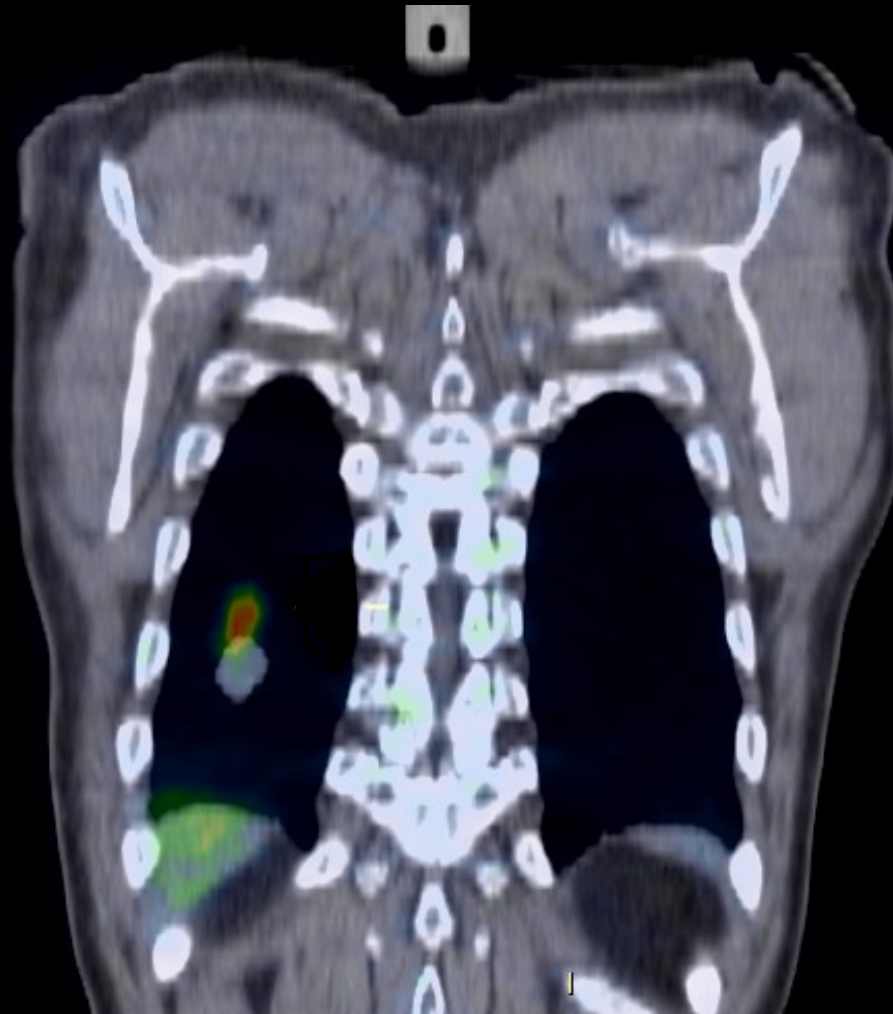


Rundhård - Solitary Pulmonary Nodule

- F 64 år
 - Rökare
 - CT: 1,5 cm
- Malignitet?
- SUV max: 1,3*

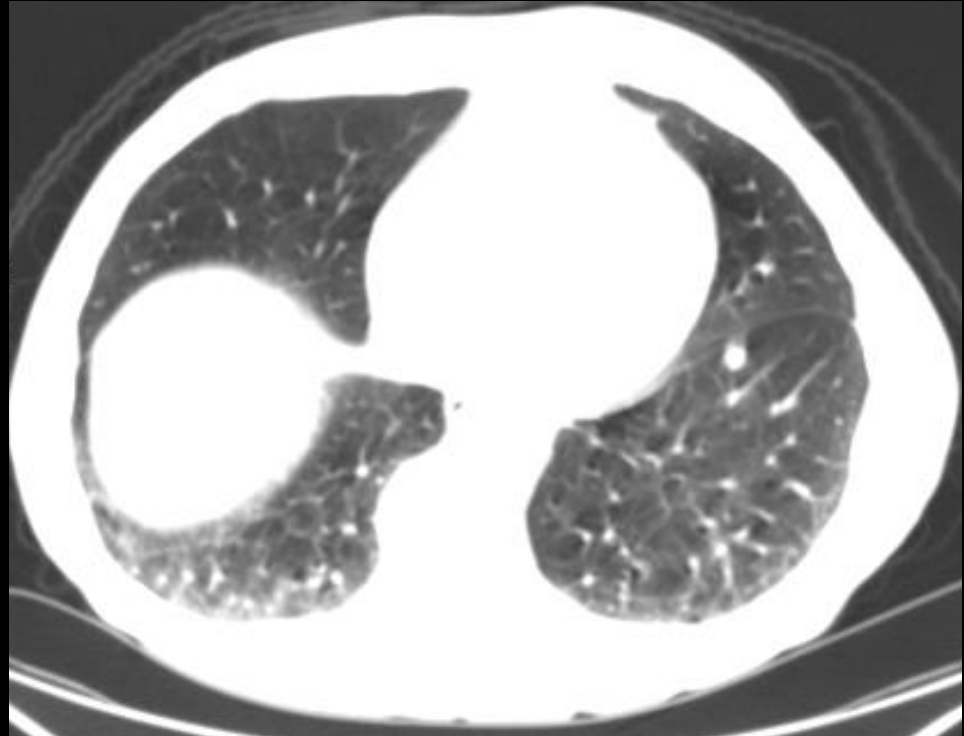


Vanlig mismatch



Rundhård - Solitary Pulmonary Nodule

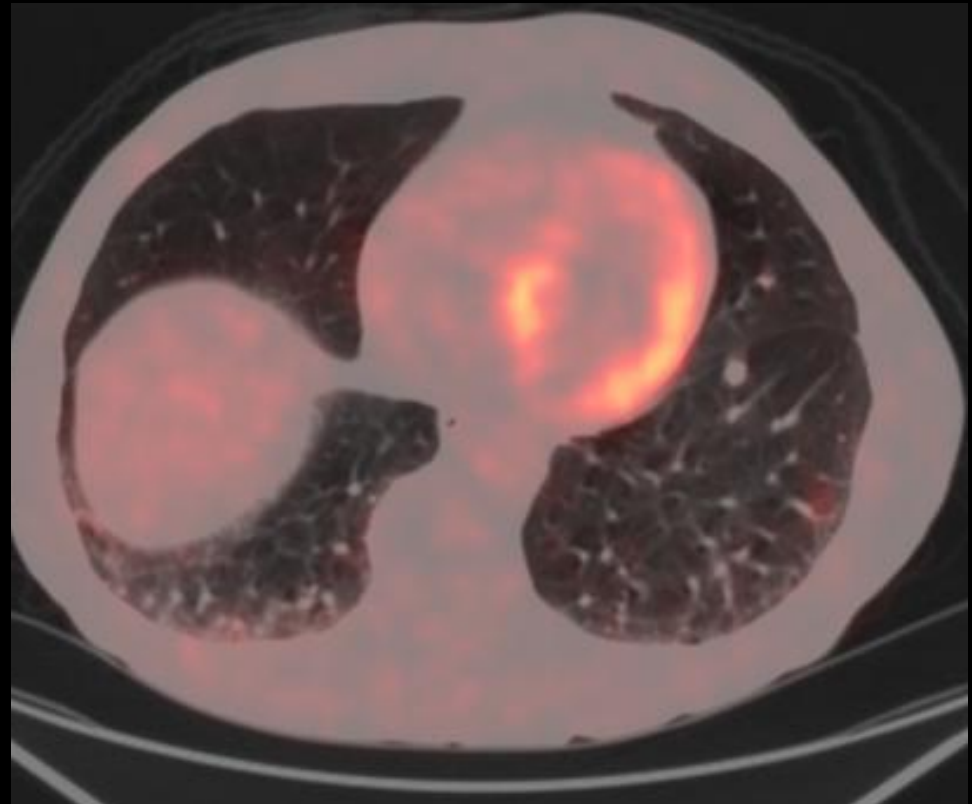
- M 48 år
- Rökare
- CT: 8 mm
Malignitet?



Rundhård - Solitary Pulmonary Nodule

- M 48 år
- Rökare
- CT: 8 mm
Malignitet?

$SUV_{max} = 1,4$



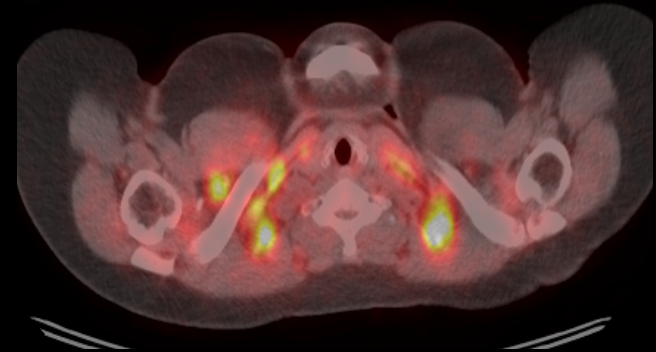
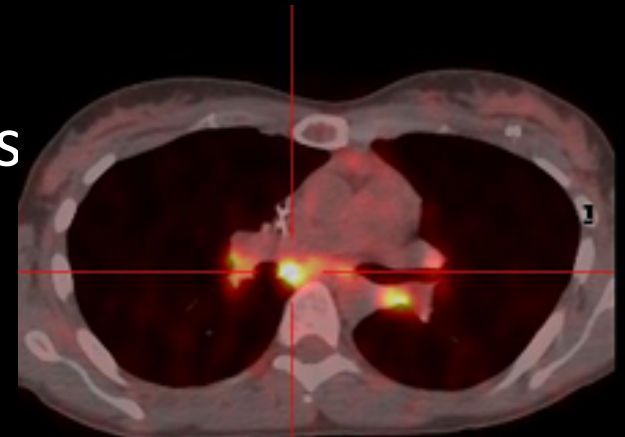
Rundhård - Solitary Pulmonary Nodule

- Storlek och täthet
 - <10 mm ska granskas med försiktighet
 - 7-8 mm är PET- kamerans upplösning
 - Andning ger partiell volymseffekt
 - En negativ PET utesluter inte malignitet i små förändringar

Glesa och mixade SPN (50/50 risk malign/
infl)

Rundhård - Solitary Pulmonary Nodule

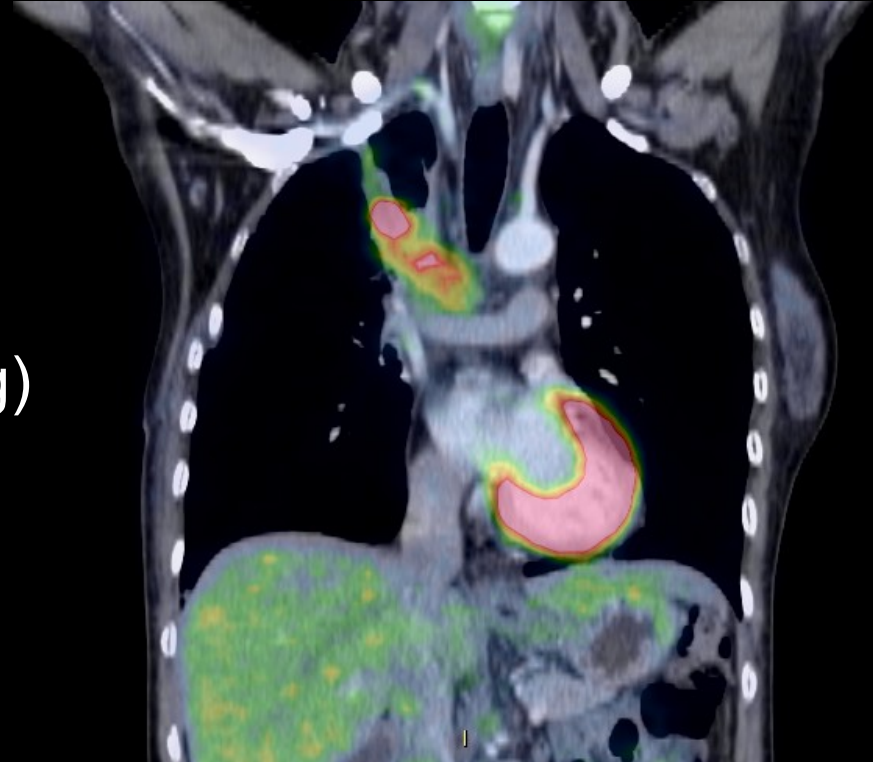
- Falskt negativ PET
 - Bronkioloalveolär cancer, carcinoider
- Falsk positiv PET
 - Inflammatorisk/infektiös genes
 - TB, sarkoidos, granulom
 - Iatrogen
 - Invasiva ingrepp som biopsi
 - Strålbehandling
 - Fysiologiska upptag
 - Brunt fett

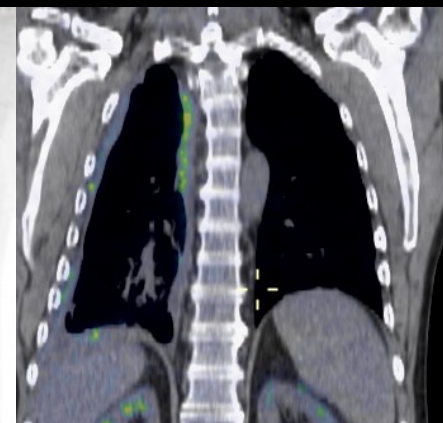
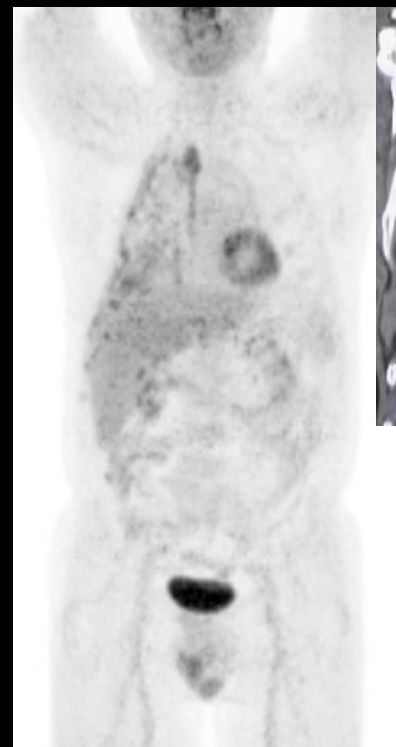
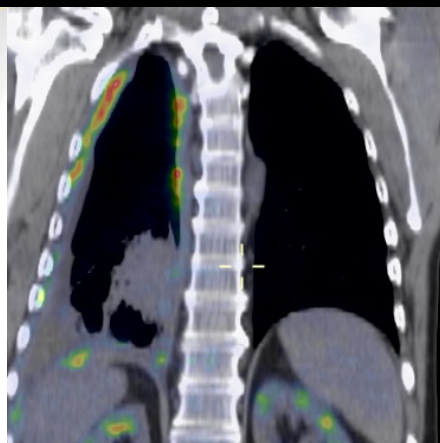
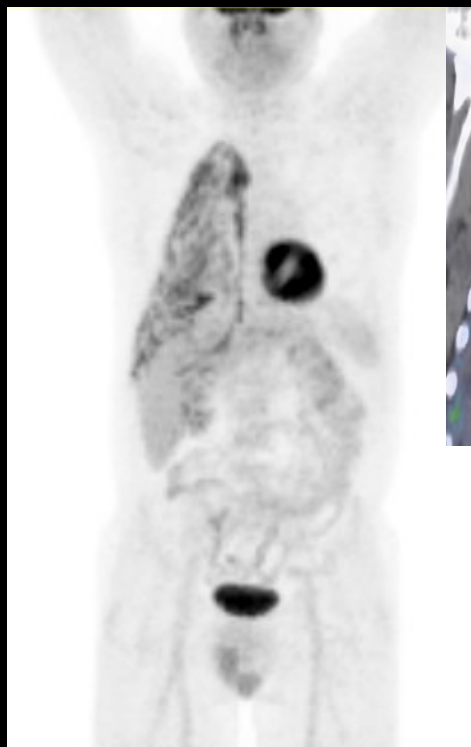


PET-DT för DOSPLANERING

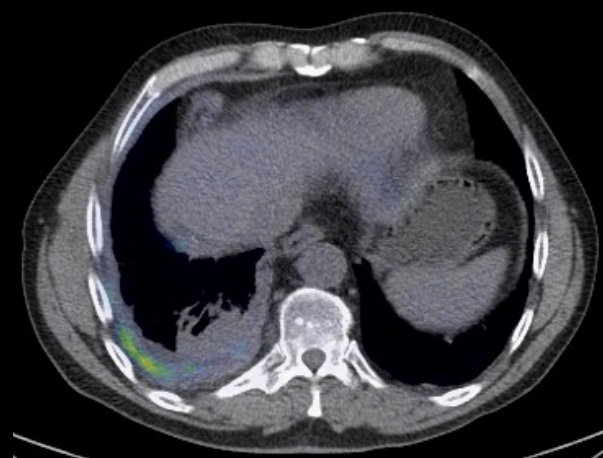
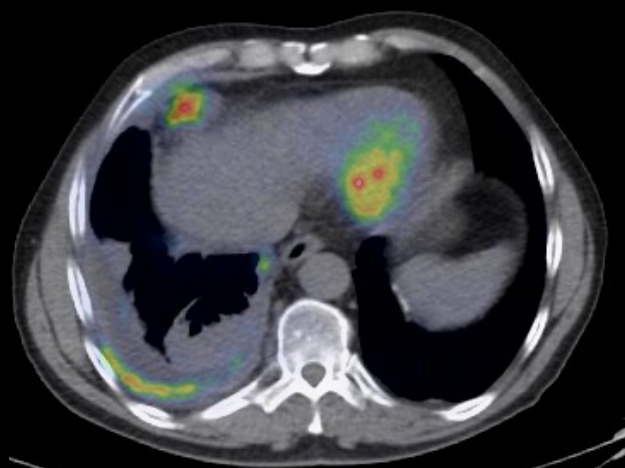
Sedan feb 2011 rutin
Patienter aktuella för
radiokemoterapi (icke-
småcellig IIIA-B)
PET/CT i fixation (fri andning)

Multidisciplinär utvärdering
av GTV (Gross Tumor
Volume)





BL (feb) och FU
efter 4 cytokurer
(maj)



Mesotheliom

Sammanfattning FDG PET-DT

- Hög sensitivitet
- Negativ PET/CT—låg risk för malign tumör
- Positiv PET/CT— är inte liktydig med malign tumör
- Icke småcellig lungcancer -- Etablerad metod för kartläggning av tumörutbredning och stadiumindelning
- Dosplanering
- Multidisciplinär konferens
- FoU-indikation: Recidiv och terapirespons, andra primära lungtumörer

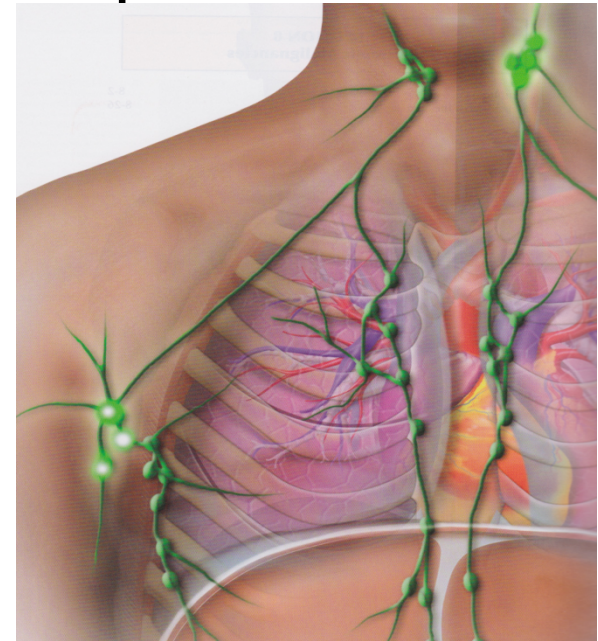
18F-FDG PET/CT och kliniska indikationer

	<u>Stadiumindelning</u>	<u>Behandlingsrespons</u>	<u>Recidiv</u>
Lunga	++++	+	+++
Lymfom	++++	++++	++
Malignt melanom	++	+	+++
Head- och Neck	++++	+	++
Kolorektal	+++		+++
Esofagus	++		++
Oklara primärtumörer	++++		
Gyn (cervix och ovarial)	+		+
Bröst	+++		++
Prostatacancer	Andra tracers		



Lymfom

- Delas traditionellt in i
 1. Hodgkins lymfom
 2. Non-Hodgkins lymfom
- Diagnosen ställs baserat på histopatologi
- Kliniskt delas de in i
 - Högmaligna
 - Lågmaligna



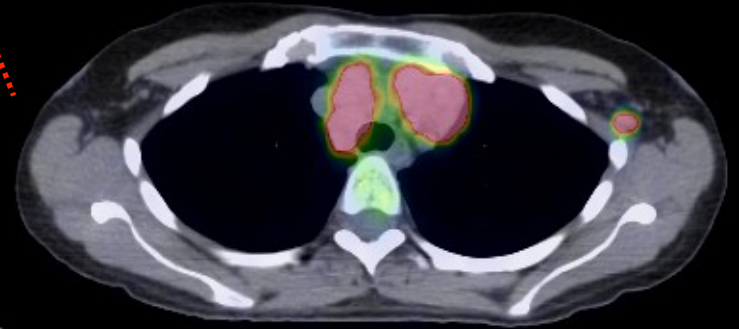
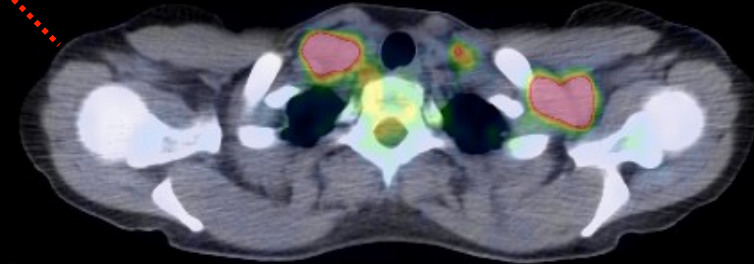
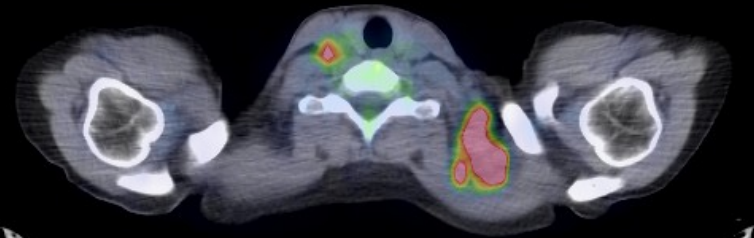
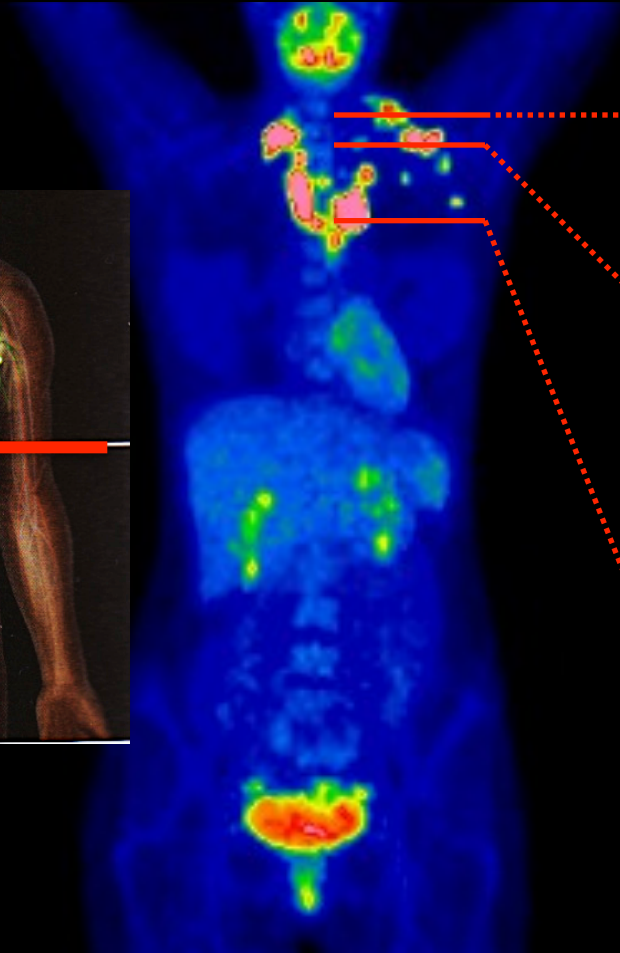
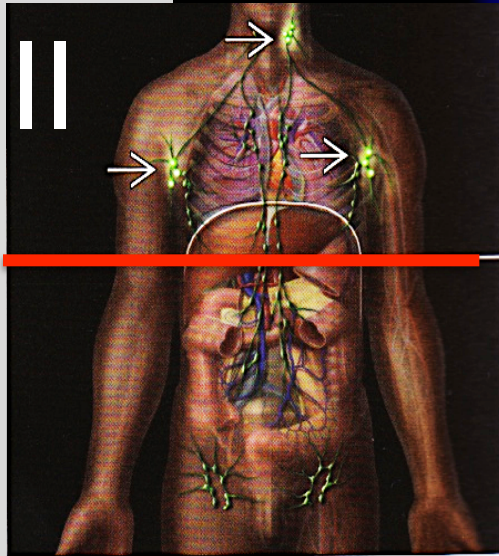


UPPSALA
UNIVERSITET

Hodgkins lymfom

Stadiumindelning

FDG PET/CT (transaxial)



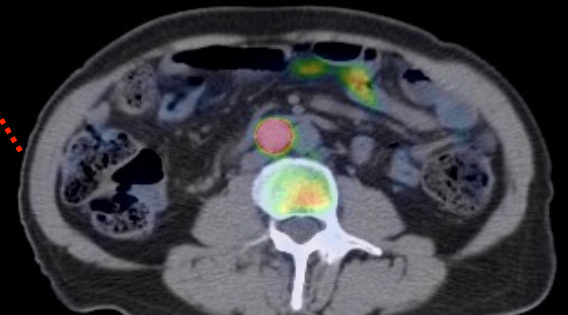
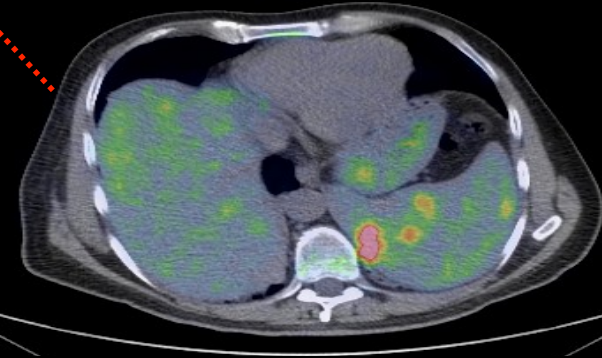
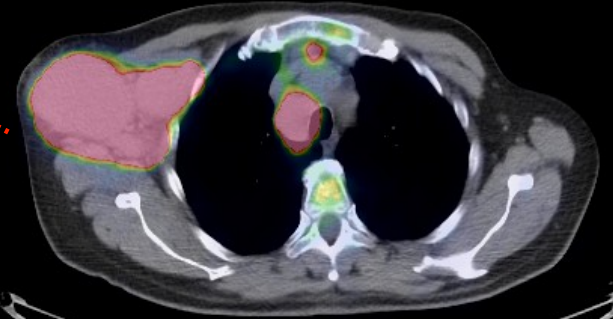
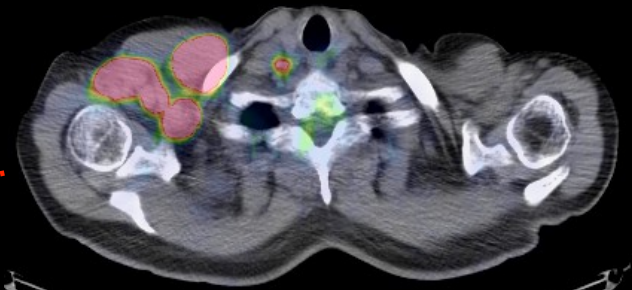
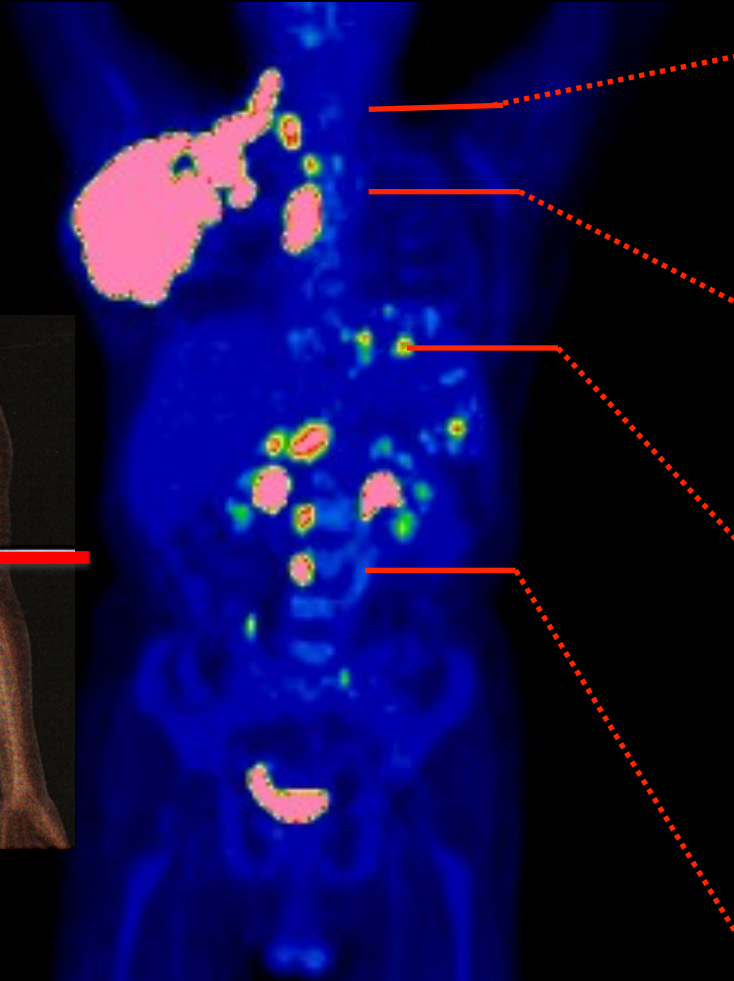
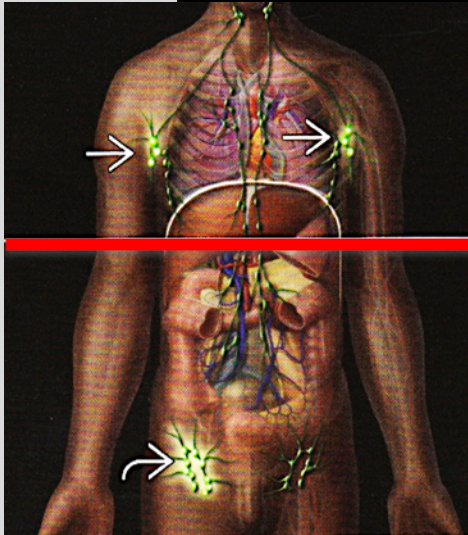
Lymfkörtellokaler



UPPSALA
UNIVERSITET

Hodgkins lymfom

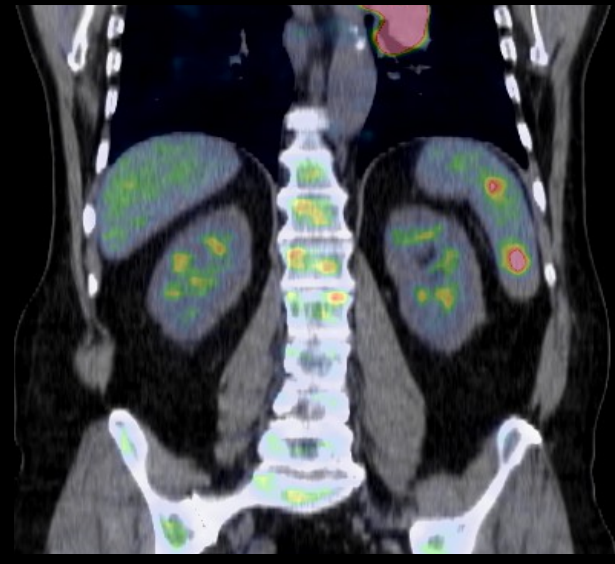
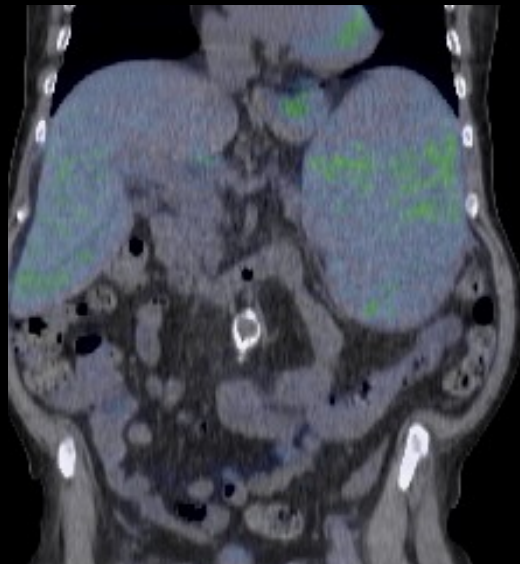
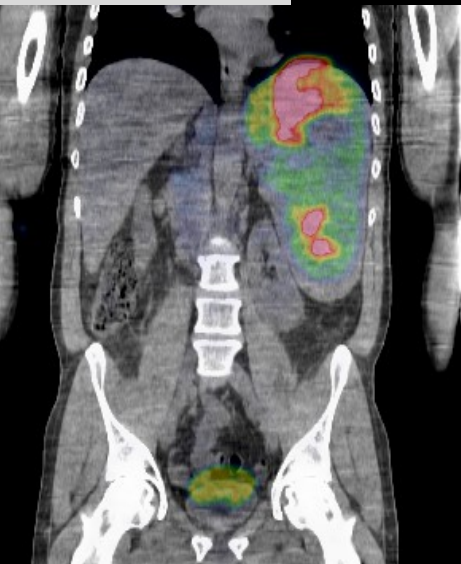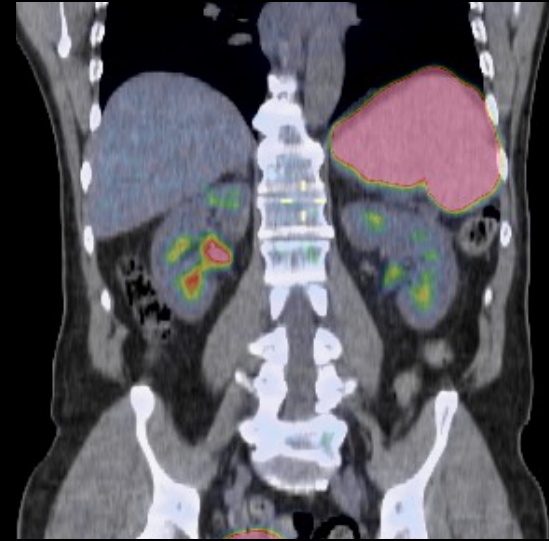
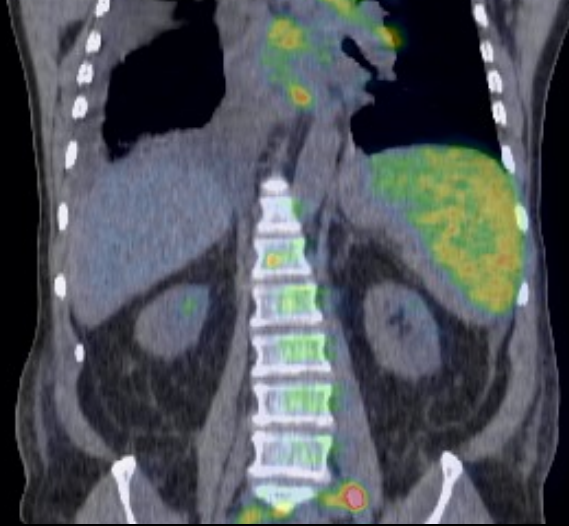Stadiumindelning





UPPSALA
UNIVERSITET

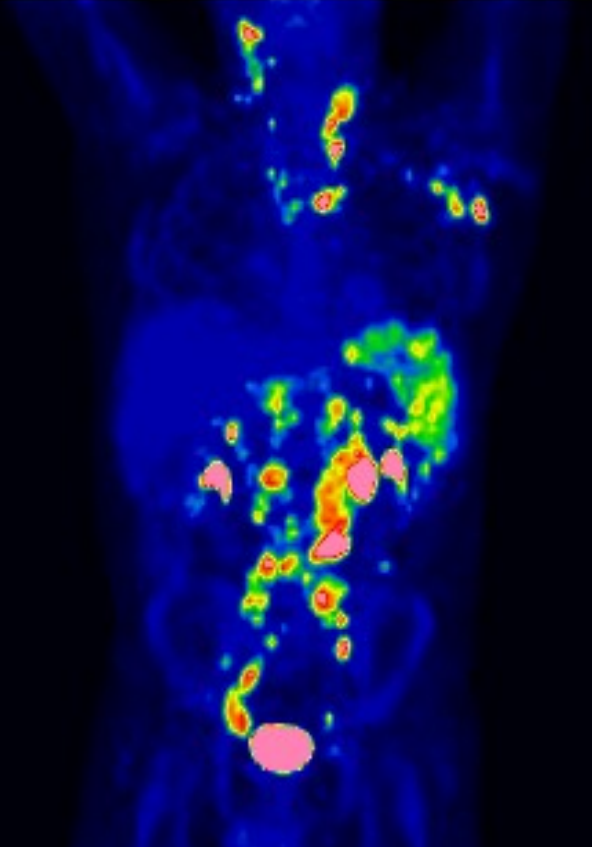
Olika mjältupptag



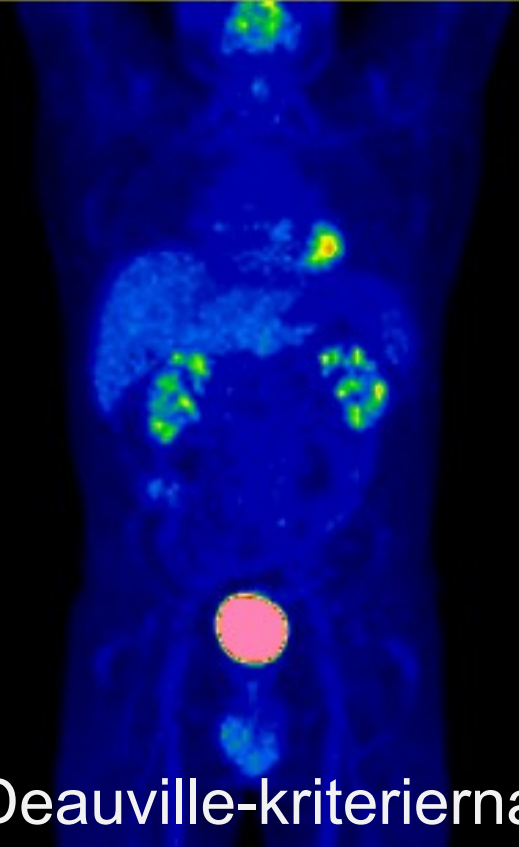


UPPSALA
UNIVERSITET

Utvärdering: Terapi-respons HL



Stadiumindelning



Deauville-kriterierna

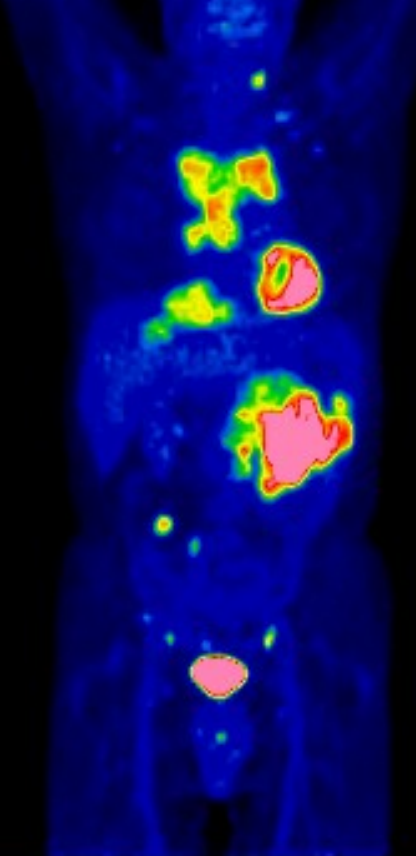
Interim

2 cykler ABVD

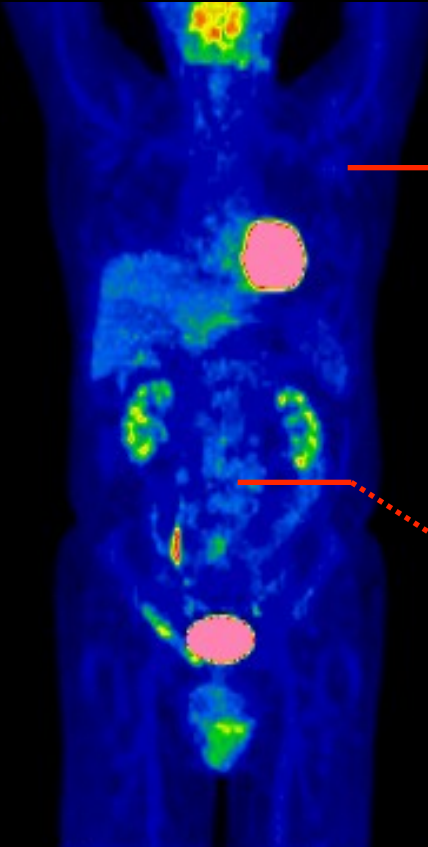


UPPSALA
UNIVERSITET

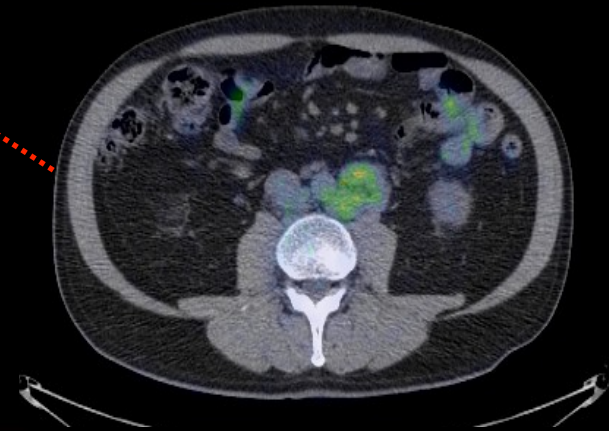
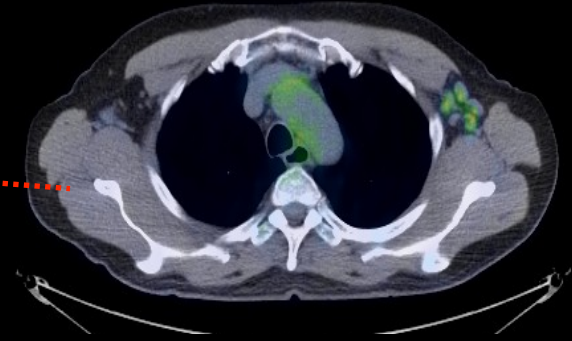
Non-Hodgkins lymfom



Högmaligt



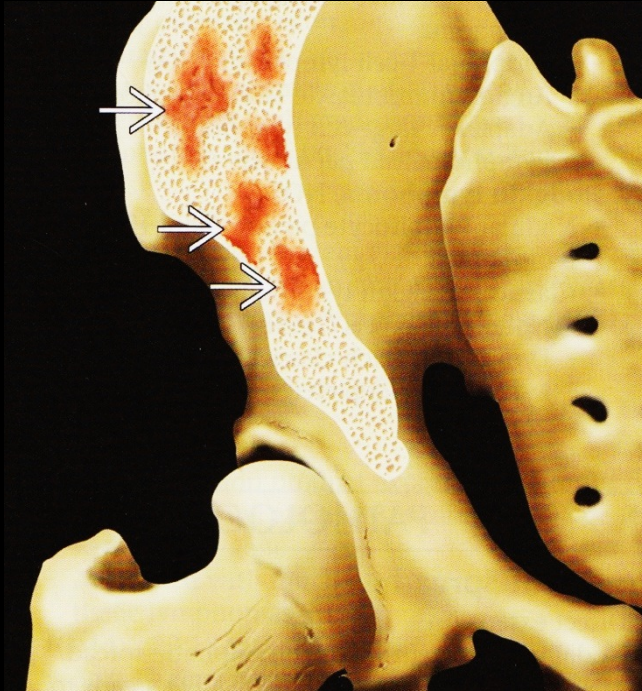
Lågmaligt



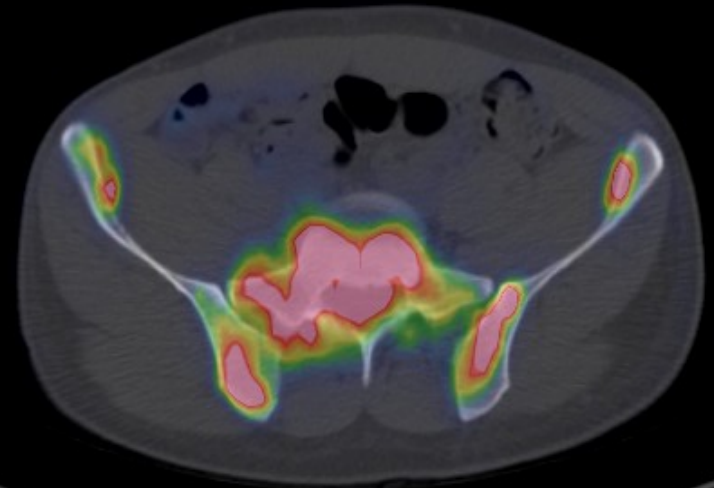
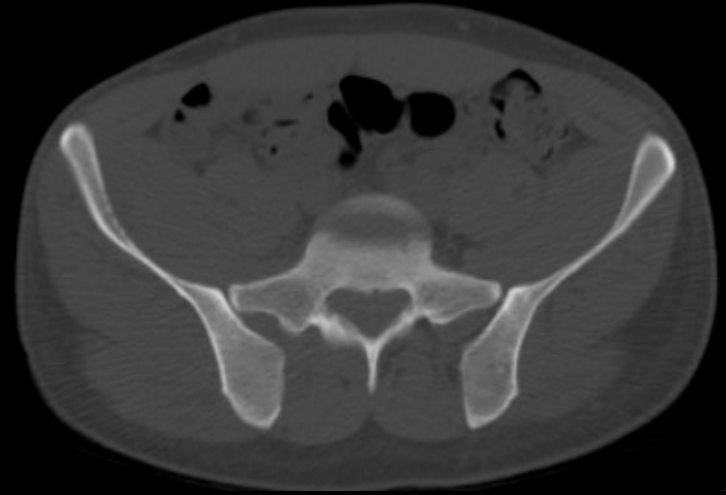

UPPSALA
UNIVERSITET

Benmärgsengagemang



CT missar ofta
benmärgsengagemang





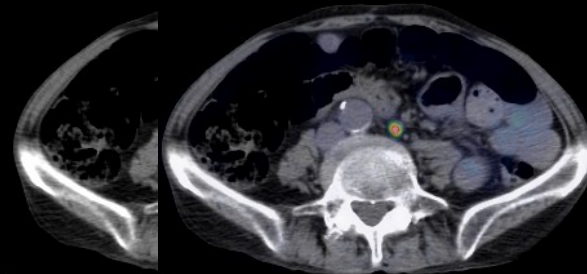
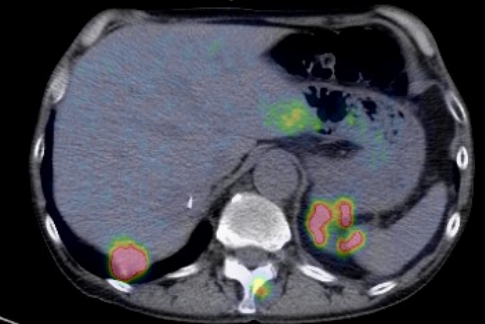
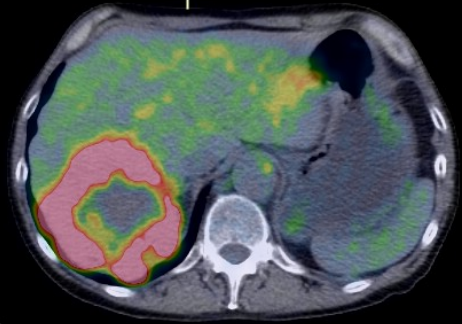
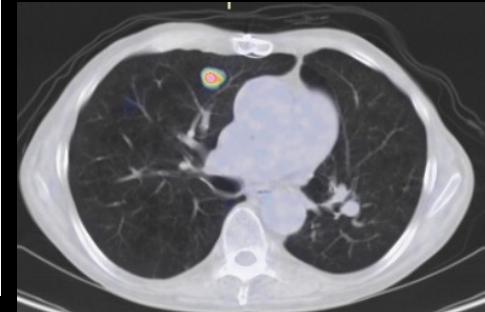
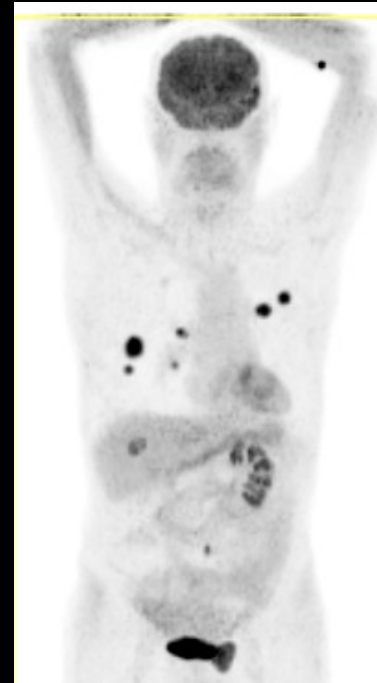
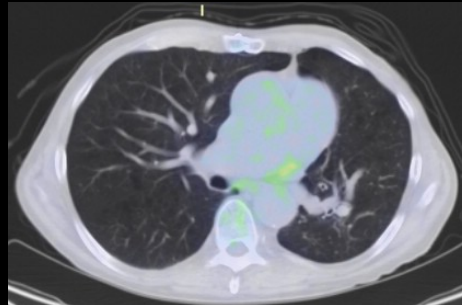
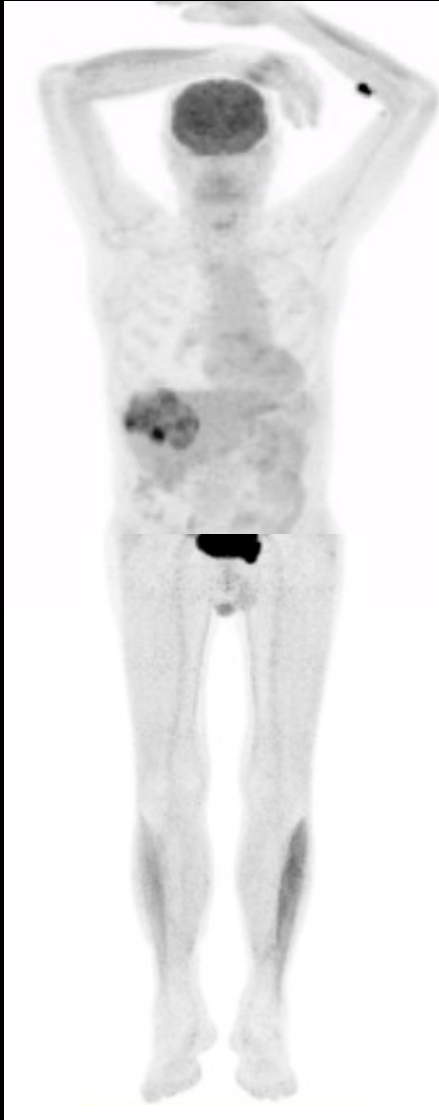FDG PET/CT Staging

- Ja, används kliniskt för HL
- Nej, för NHL-oklara fall, recidiv och transformation
- FDG PET/CT är betydligt känsligare än CT
- Kan leda till “up-staging” i tidiga stadium
- Värdefull vid planering av strålbehandling (minskar strålfältet)
- Kan FDG PET/CT ersätta benmärgsbiopsi?
 - Khan et al, ICML, 2011
 - Richardson, Leukemia & lymphoma 2012

18F-FDG PET/CT och kliniska indikationer

	<u>Stadiumindelning</u>	<u>Behandlingsrespons</u>	<u>Recidiv</u>
Lunga	++++	+	+++
Lymfom	++++	++++	++
Malignt melanom	++	+	+++
Head- och Neck	++++	+	++
Kolorektal	+++		+++
Esofagus	++		++
Oklara primärtumörer	++++		
Gyn (cervix och ovarial)	+		+
Bröst	+++		++
Prostatacancer	Andra tracers		

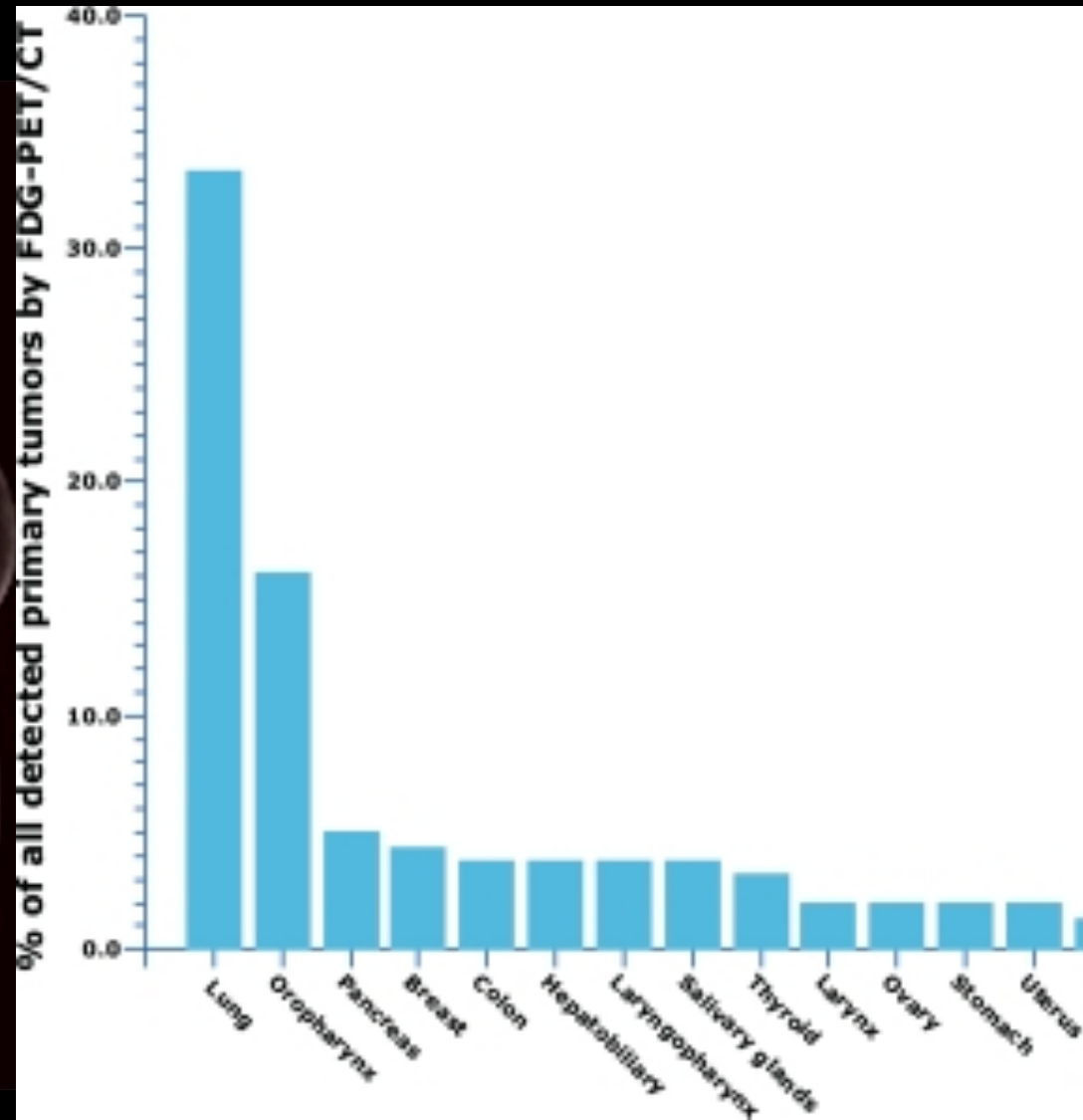
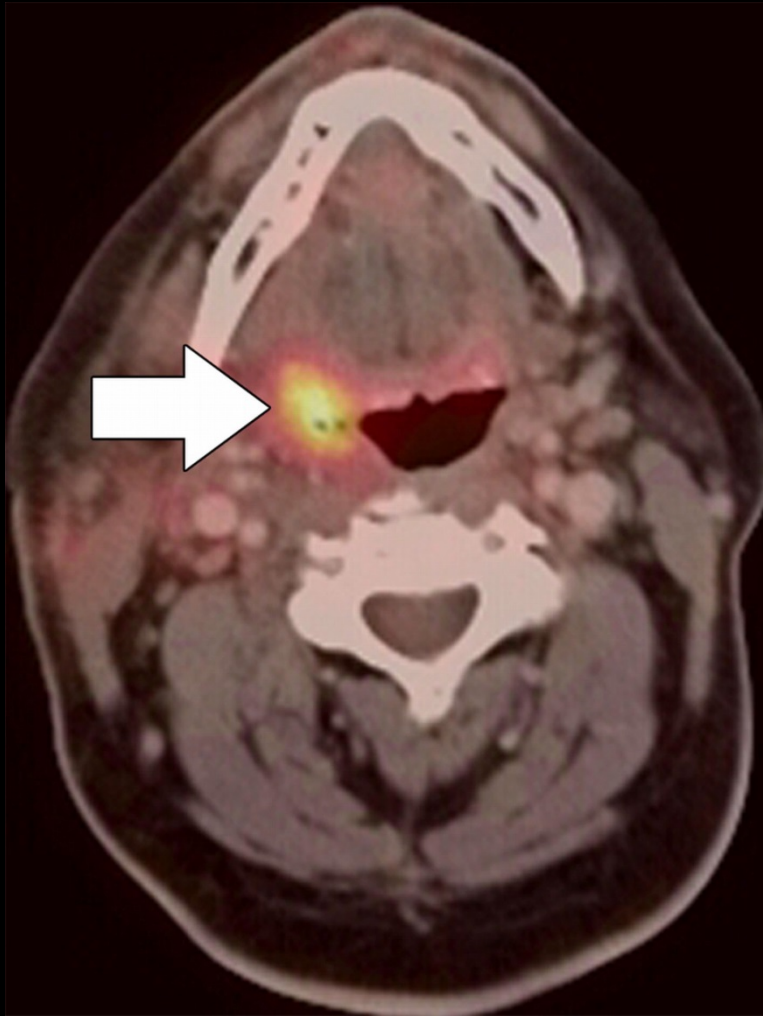
Malignt melanom- Helkropppsprotokoll



18F-FDG PET/CT och kliniska indikationer

	<u>Stadiumindelning</u>	<u>Behandlingsrespons</u>	<u>Recidiv</u>
Lunga	++++	+	+++
Lymfom	++++	++++	++
Malignt melanom	++	+	+++
Head- och Neck	++++	+	++
Kolorektal	+++		+++
Esofagus	++		++
Oklara primärtumörer	++++		
Gyn (cervix och ovarial)	+		+
Bröst	+++		++
Prostatacancer	Andra tracers		

Okänd primärtumör och FDG-PET/CT



18F-FDG PET/CT och kliniska indikationer

	<u>Stadiumindelning</u>	<u>Behandlingsrespons</u>	<u>Recidiv</u>
Lunga <input checked="" type="checkbox"/>	++++	+	+++
Lymfom <input checked="" type="checkbox"/>	++++	++++	++
Malignt melanom <input checked="" type="checkbox"/>	++	+	+++
Head- och Neck	++++	+	++
Kolorektal	+++		+++
Esofagus	++		++
Oklara primärtumörer <input checked="" type="checkbox"/>	++++		
Gyn (cervix och ovarial)	+		+
Bröst	+++		++
Prostatacancer	Andra tracers		

18F-FDG PET/CT och kliniska indikationer

	<u>Stadiumindelning</u>	<u>Behandlingsrespons</u>	<u>Recidiv</u>
Lunga	++++	+	+++
Lymfom	++++	++++	++
Malignt melanom	++	+	+++
Head- och Neck	++++	+	++
Kolorektal	+++		+++
Esofagus	++		++
Oklara primärtumörer	++++		
Gyn (cervix och ovarial)	+		+
Bröst	+++		++
Prostatacancer	Andra tracers		