

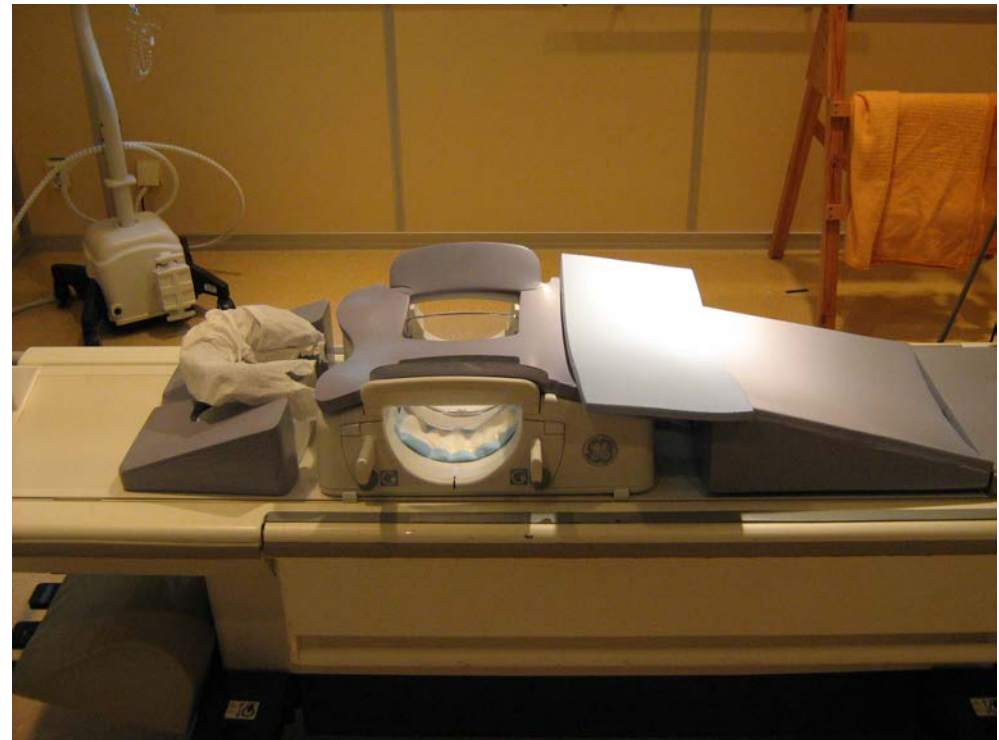
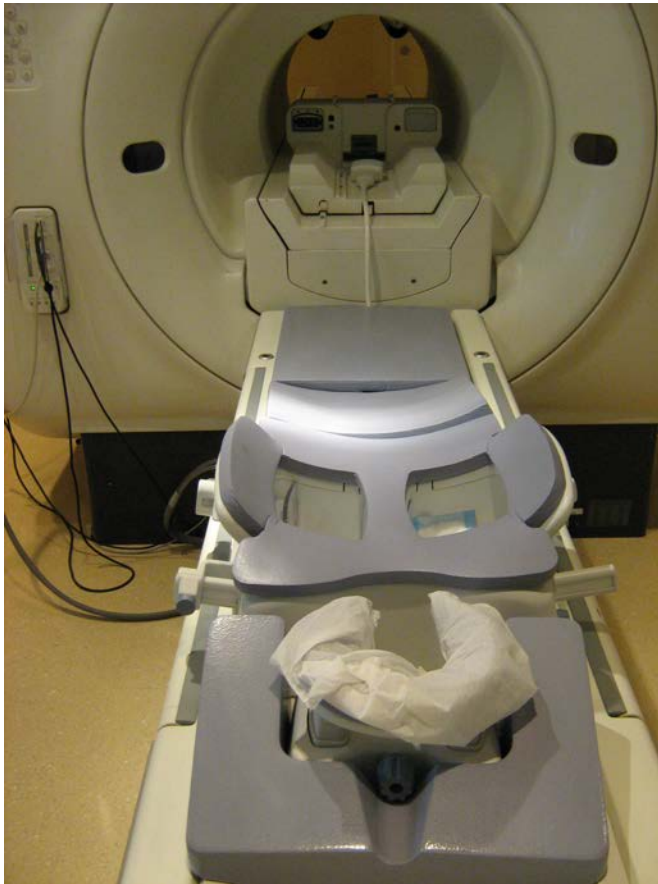MR-ledd bröstpunktion erfarenhet från S:t Görans sjukhus Stockholm



- Marina Janicijevic
- Kjell Hågemo
- Anders Karlsson
- Brigitte Wilczek


Röntgenveckan 2013
Uppsala
4 september

GE 1,5 T Signa HDx 8-kanalers bröstspole



MR-guidad vakuumbiopsi

- Reducerat MR protokoll i bröstspole med grid – komprimerat bröst
 - 1 sagitell T1 (utan fat sat)
 - 3 sagitella T1 (fat sat) sekvenser 1 före och 2 efter kontrast.
 - 1 axial T1 (fat sat)
- Stereotaxtisk beräkning med Sureloc® Confirma
- Lokalanestesi utan och med Adrenalin
- Bard Vacora® 10 Gauge (2,6 mm) vakuumbiopsi med MR kompatibel cannula
- Kolindikering efter punktion



Bröstpunktion

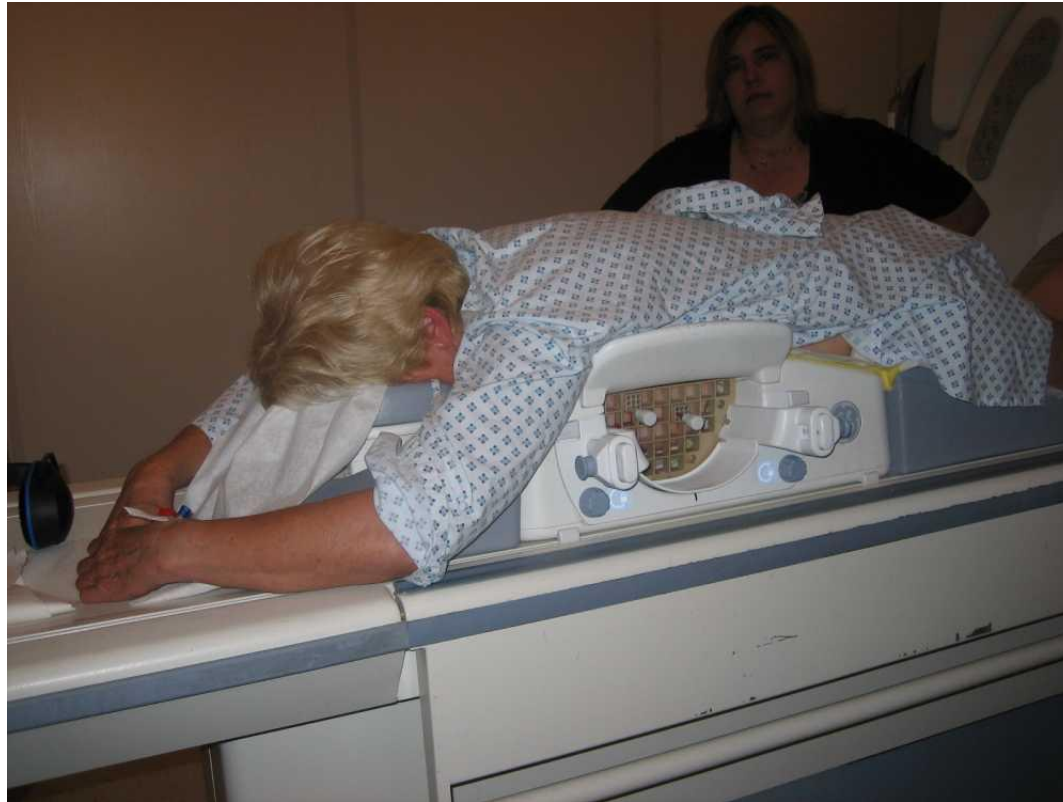Fördelar:

MR detekterade förändringar - ej visualiserbara med mammografi och UL

Nackdel:

Tidskrävande

BUKLÄGE

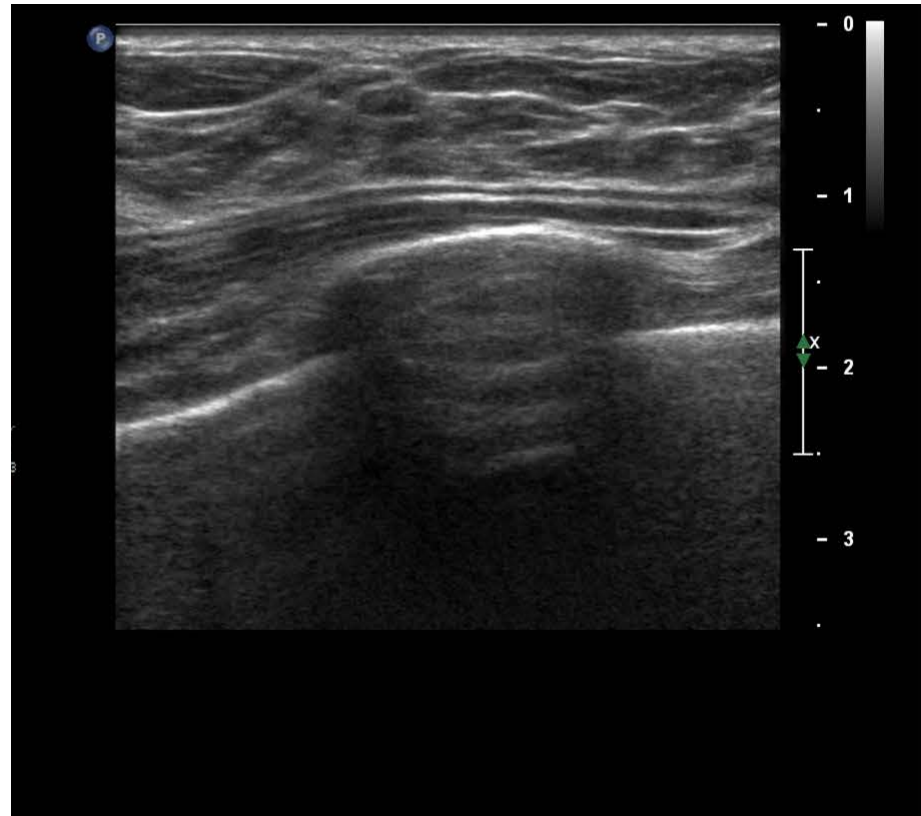
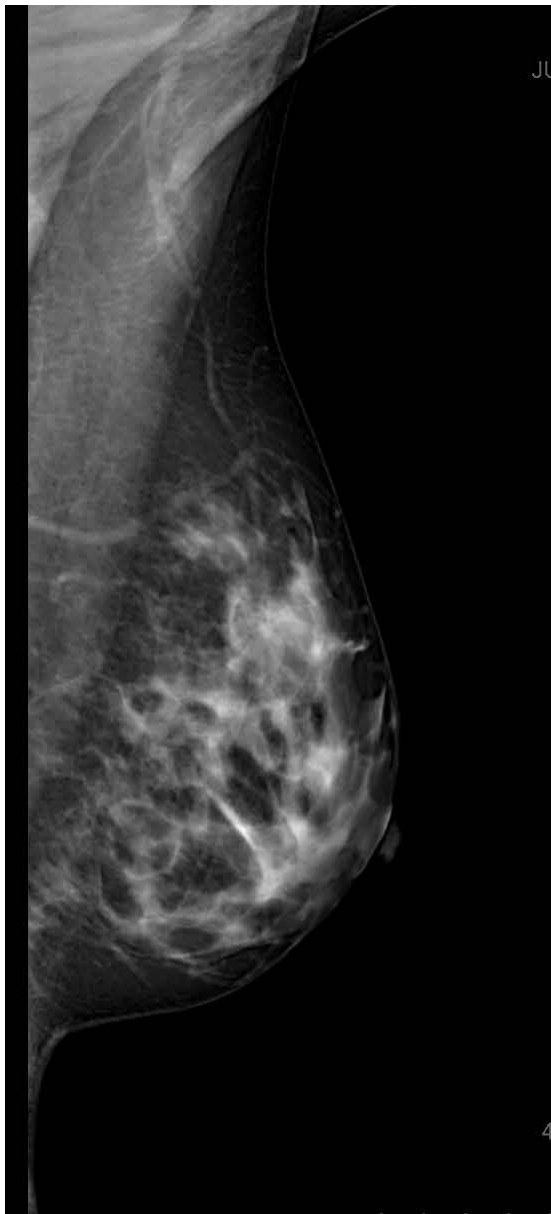
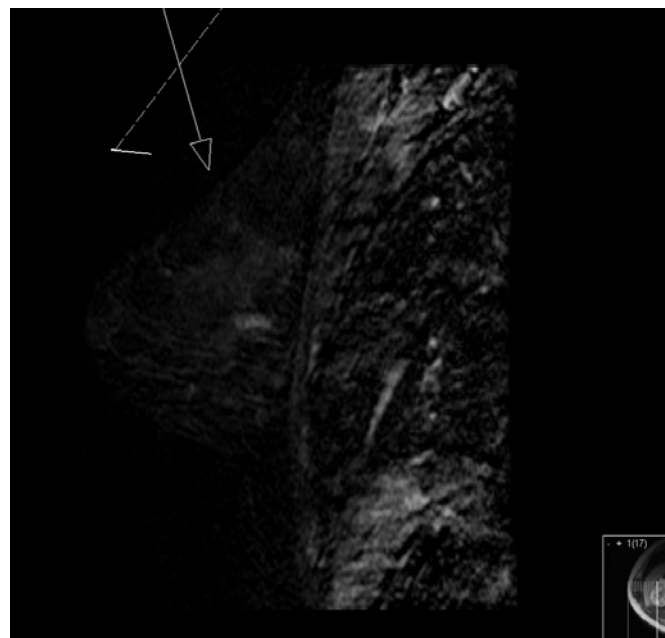
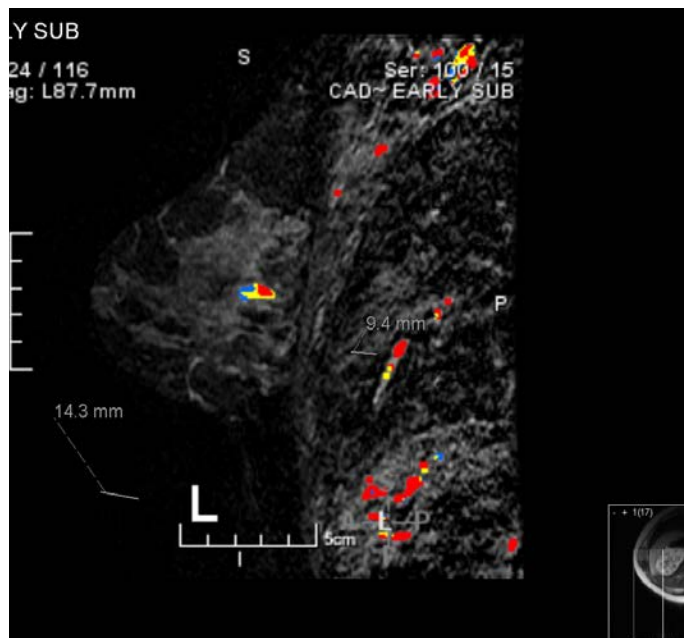
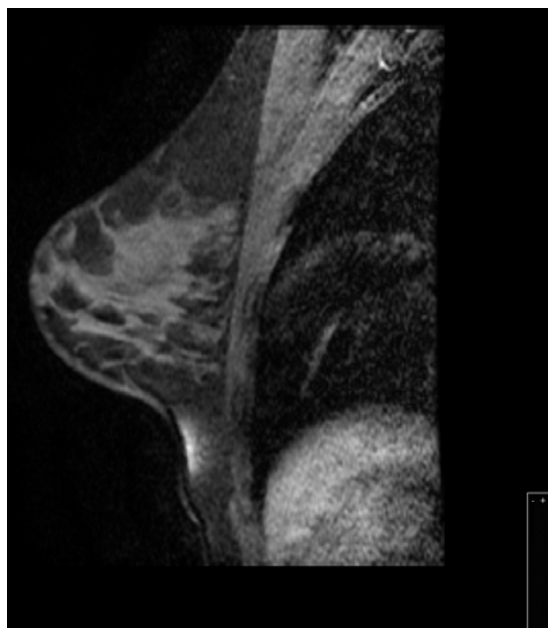
40 år

BRCA 1 mutation

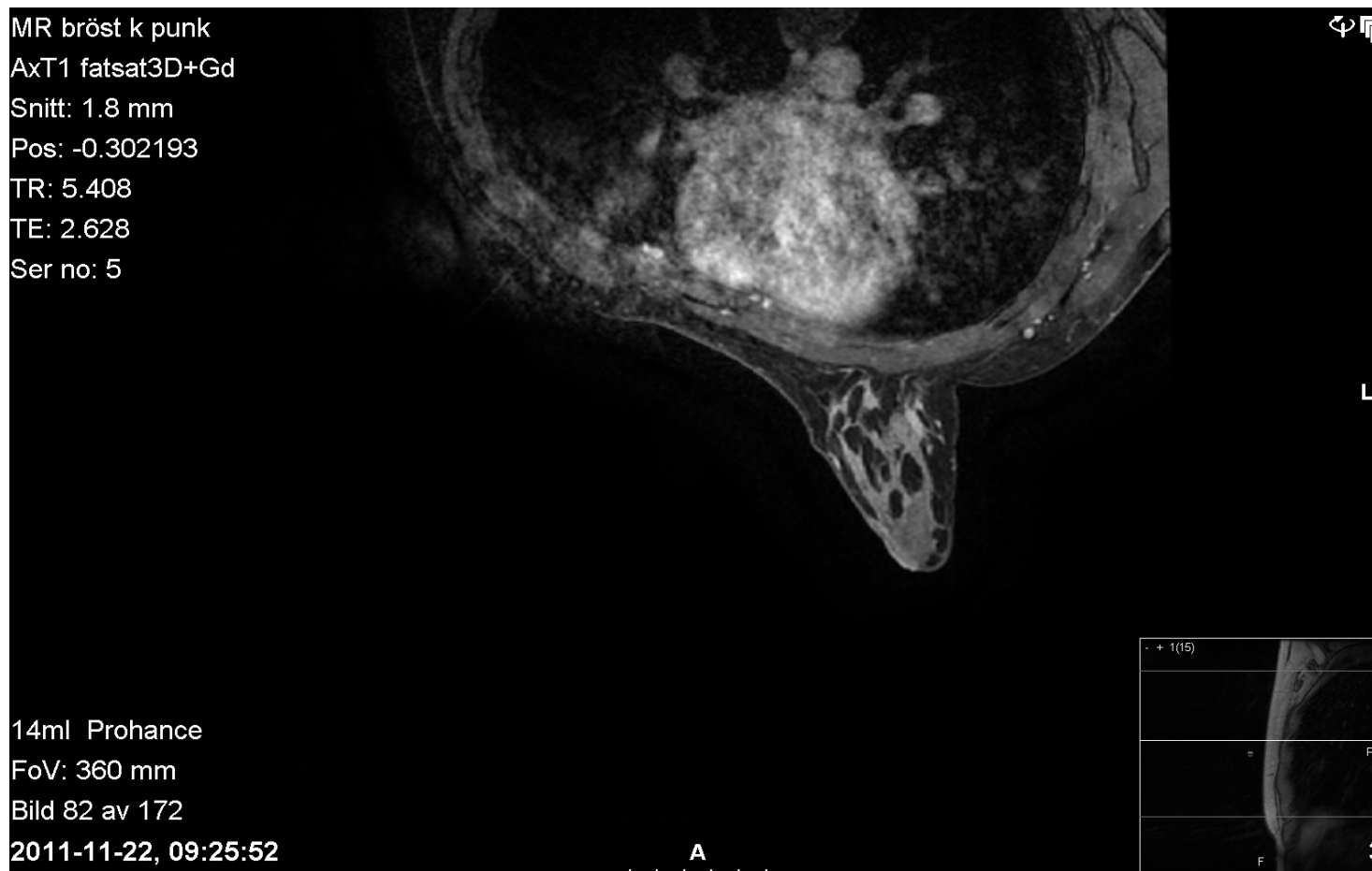
Högersidig mastektomi pga bröstcancer vid 35 år

Nu på årlig MR-Kontroll

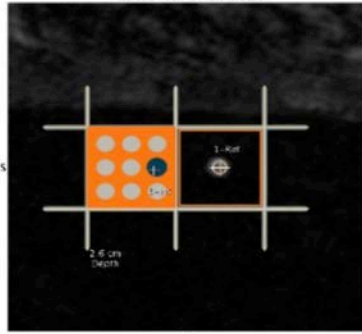




Innan punktion identifieras lesionen ånyo



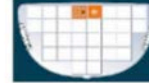Lateral view of left breast



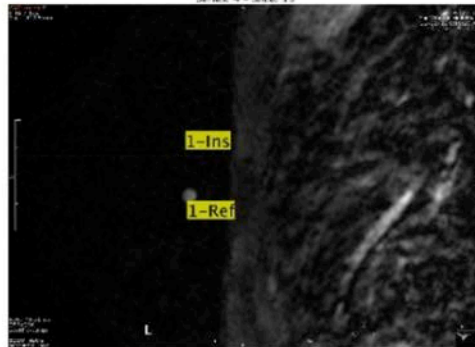
Move relative to the reference point:

Distance	Direction	Toward
0 bit* (0.1 cm)	Anterior	nipple
1 bit* (1.5 cm)	Superior	Head
2.6 cm	Depth	@includes 1.0 cm guides

Method: Grid: Band: Vectors

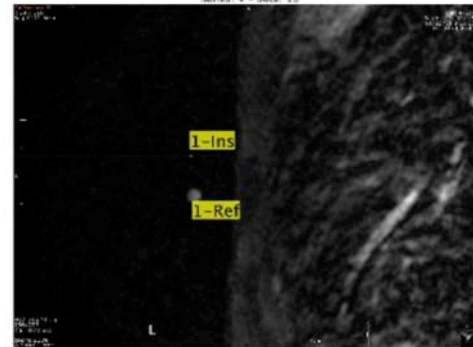


Series: 4 - Slice: 19

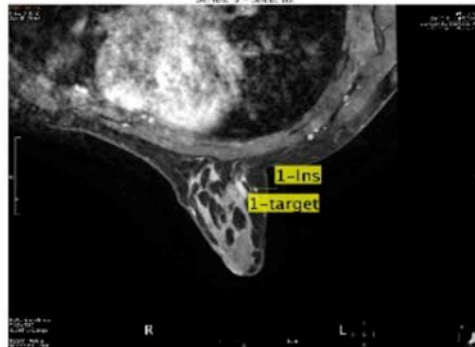


* Assumes Reference is in center of grid block

Series: 4 - Slice: 19



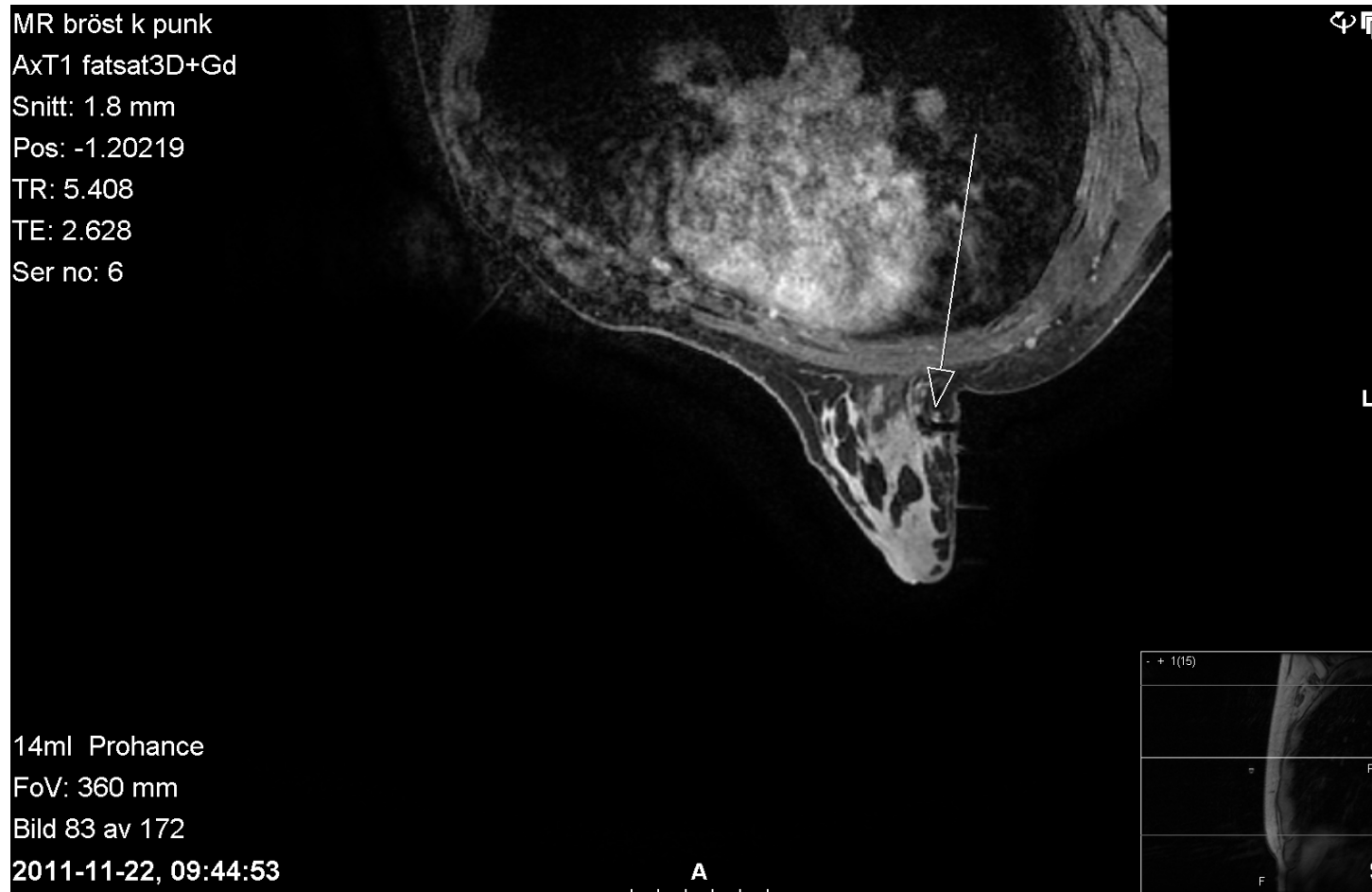
Series: 5 - Slice: 87



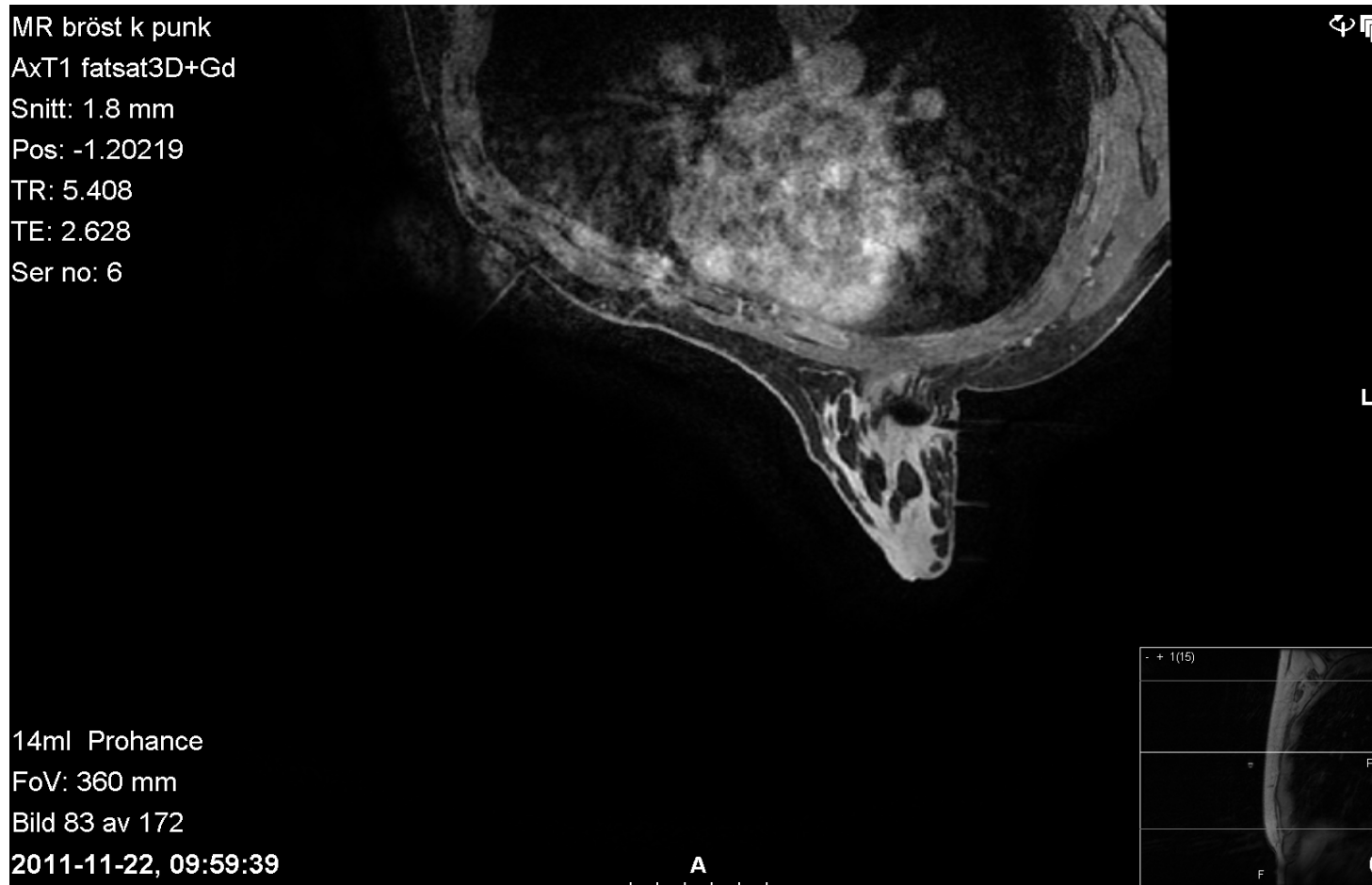
MR kompatibel mandräng



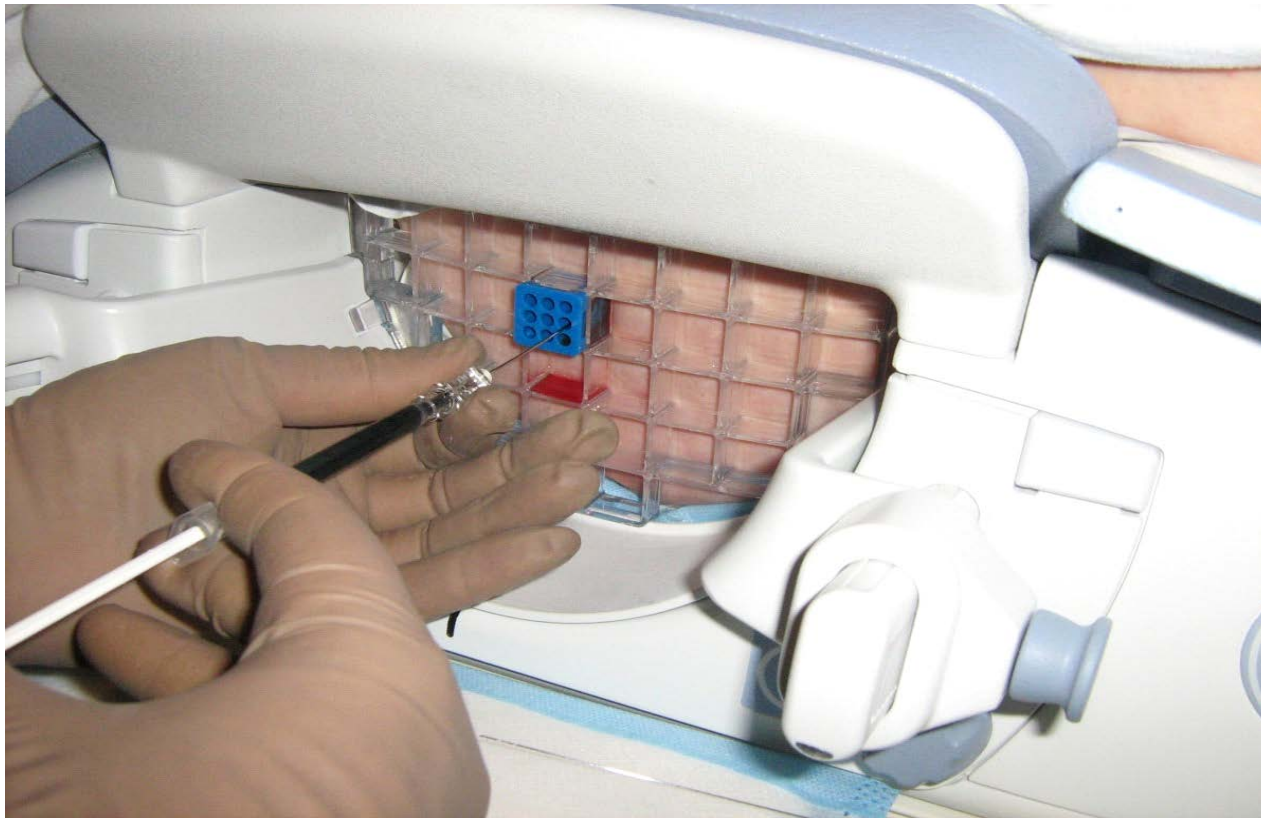
Mandräng på plats mot lesionen



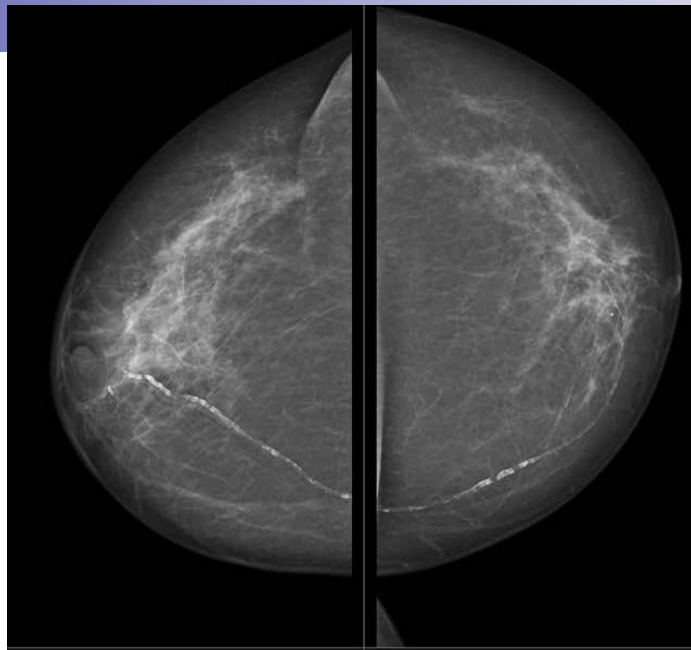
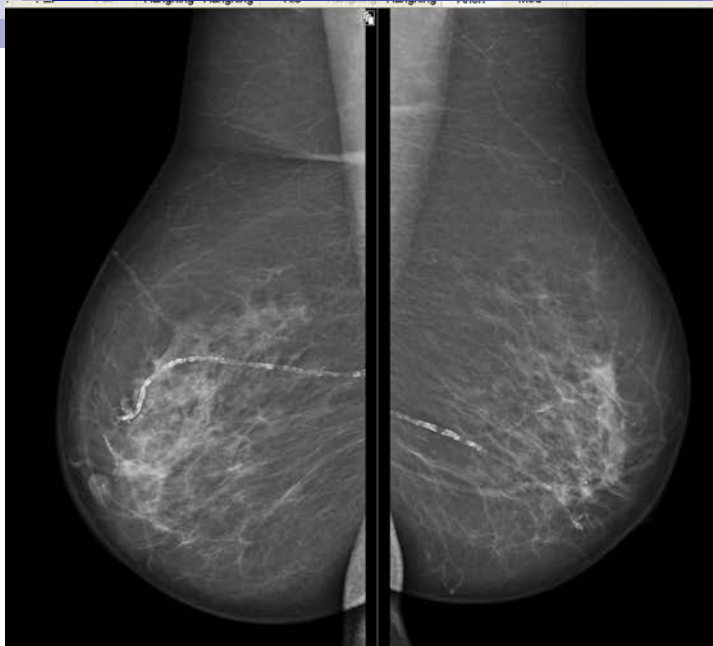Kontroll efter Biopsi



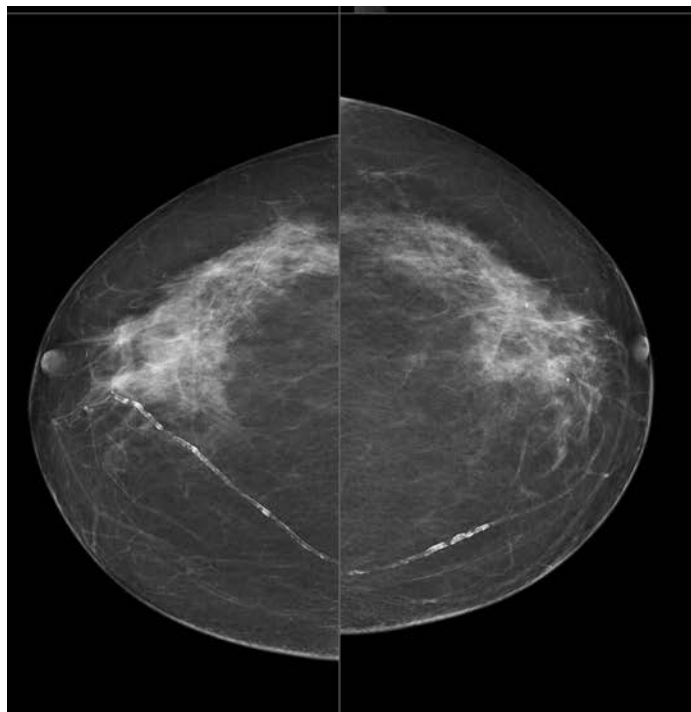
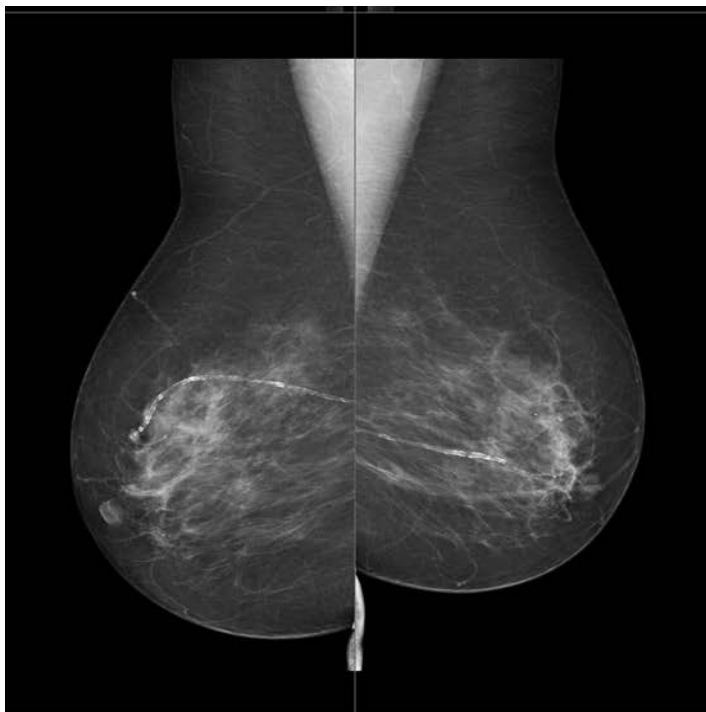Avslutande kolindikering



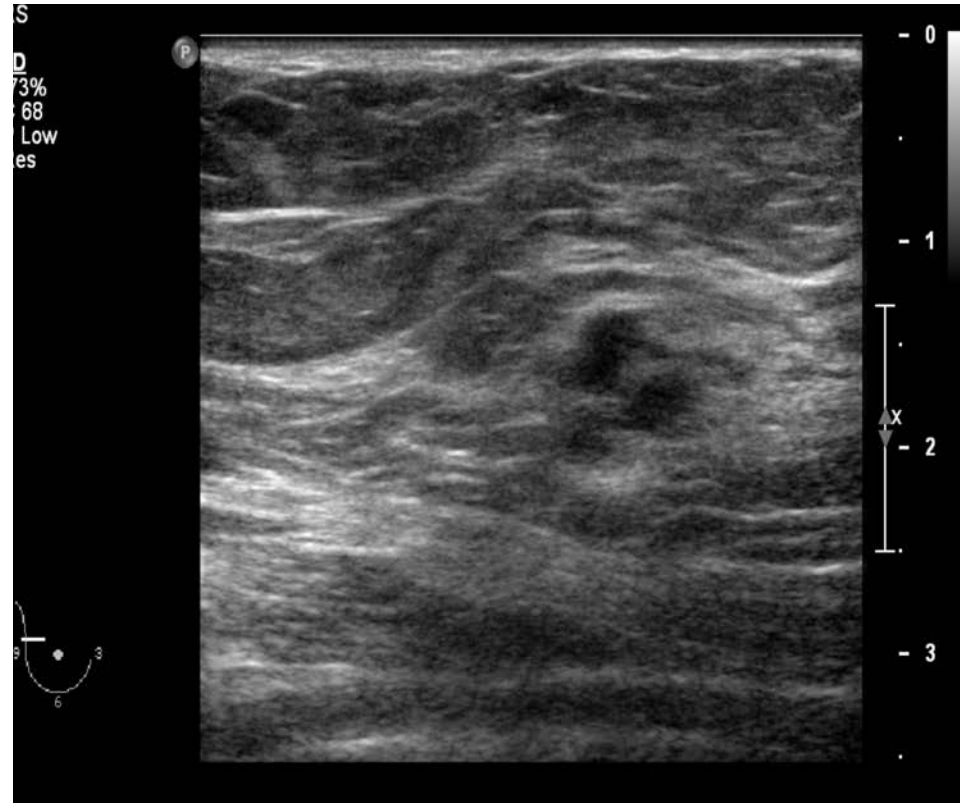
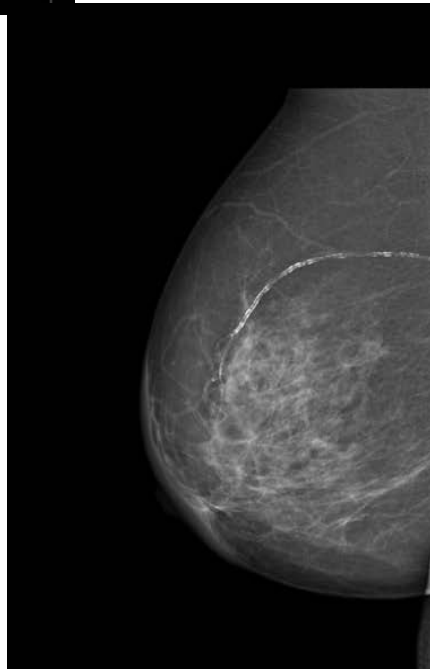
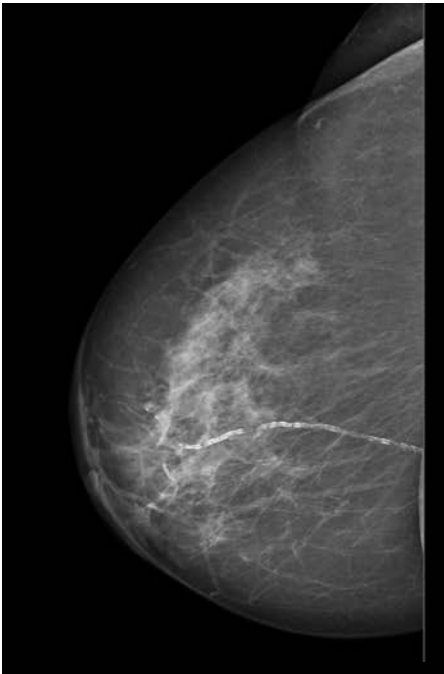
- 71 år
- Känd:
 - en drygt centimeter stor Tu i höger bröst
 - en metastas i höger axill

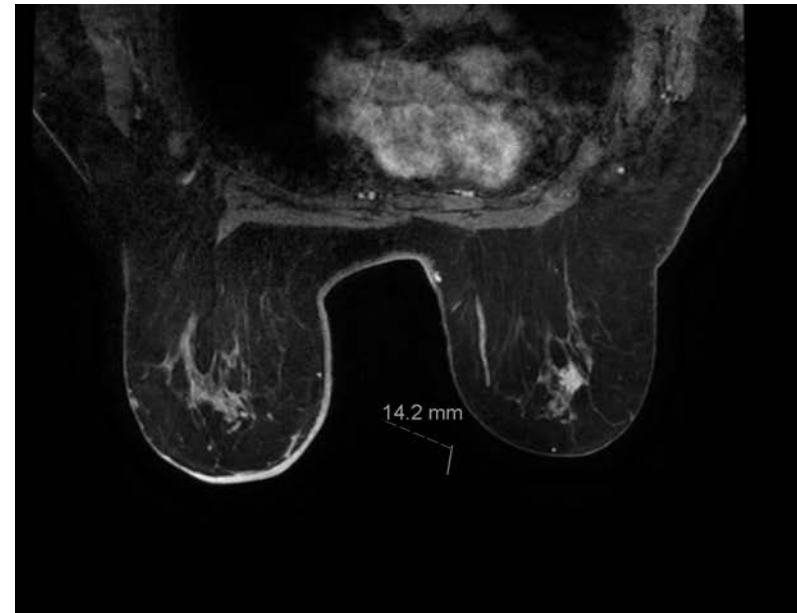
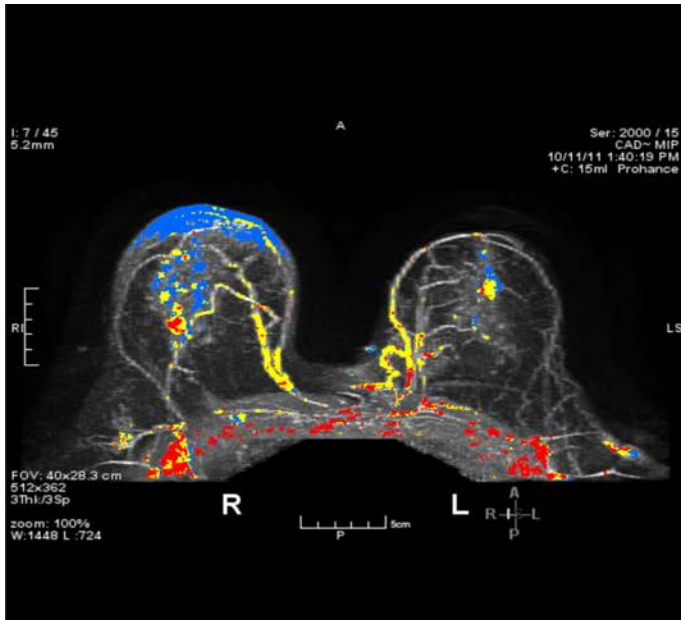
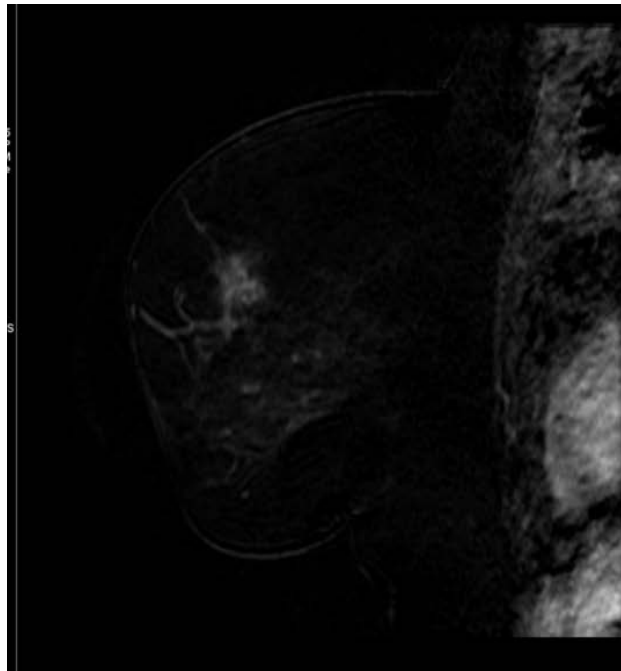


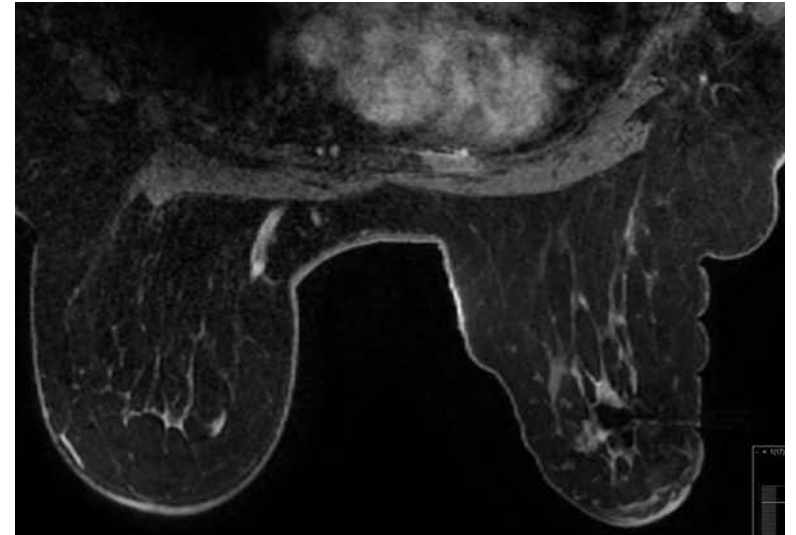
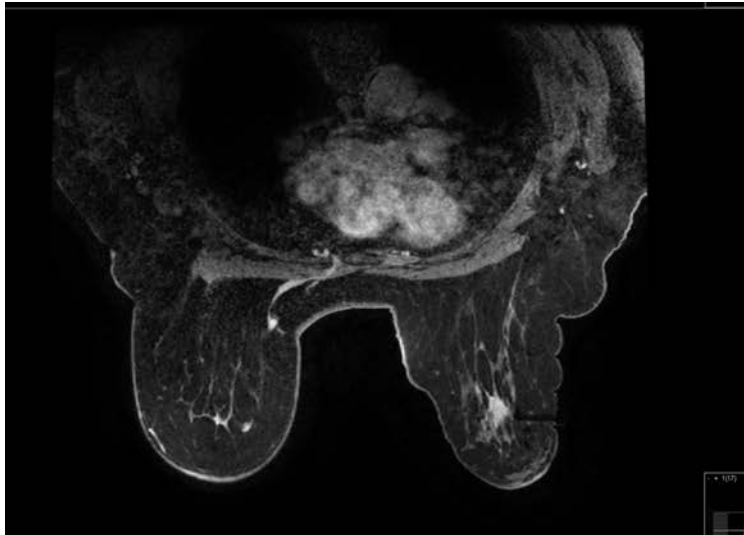
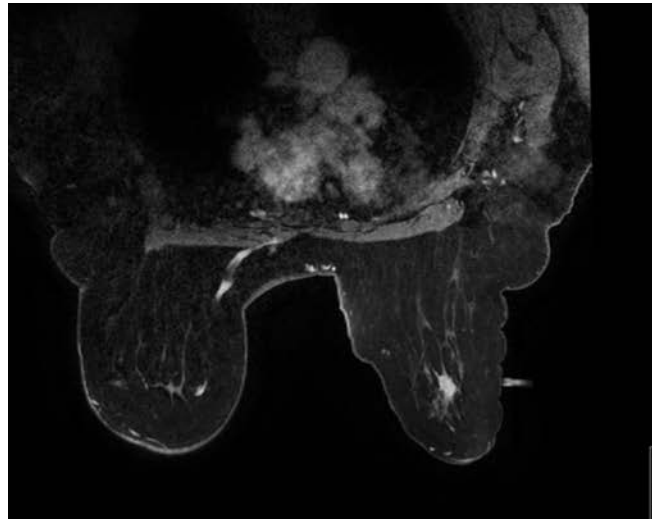
2011



2009

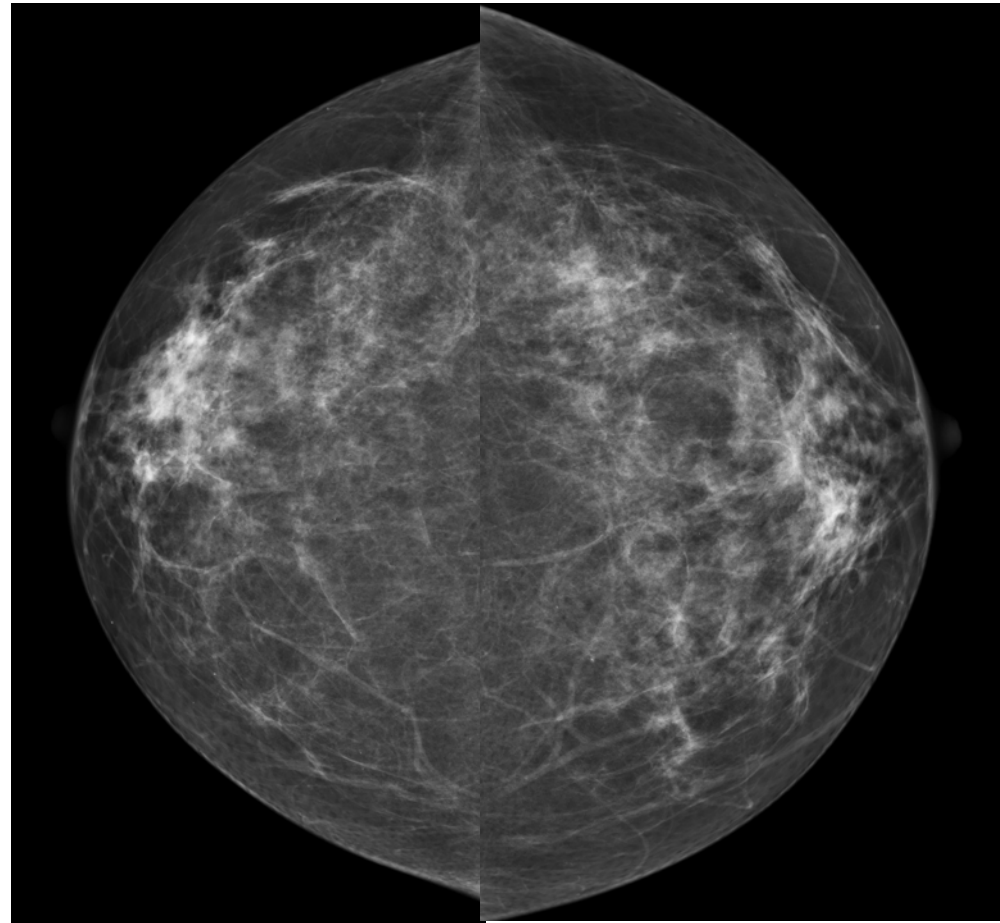
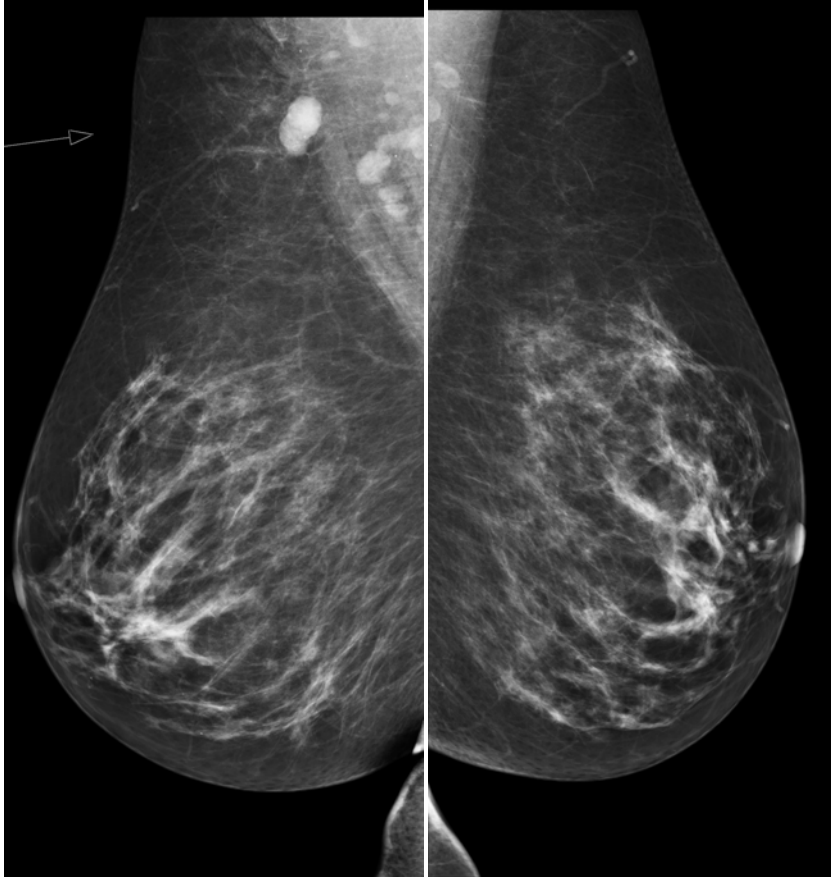


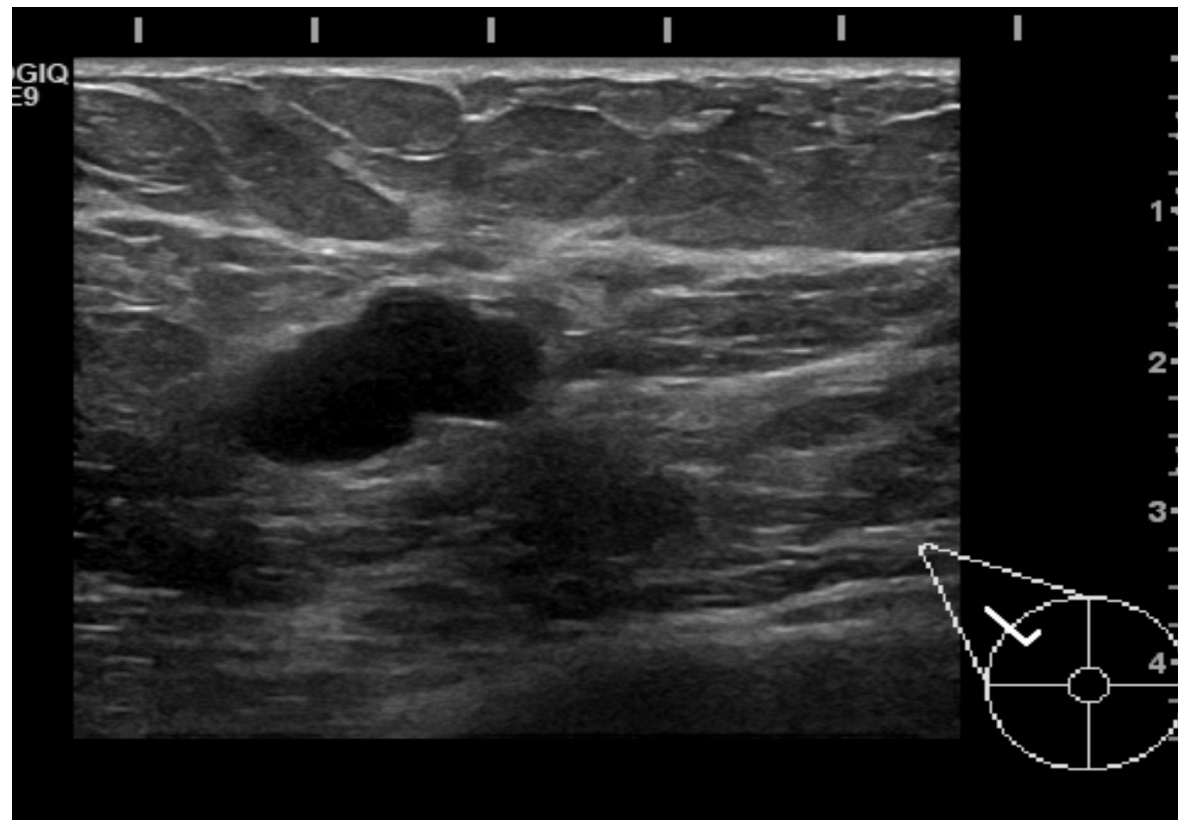


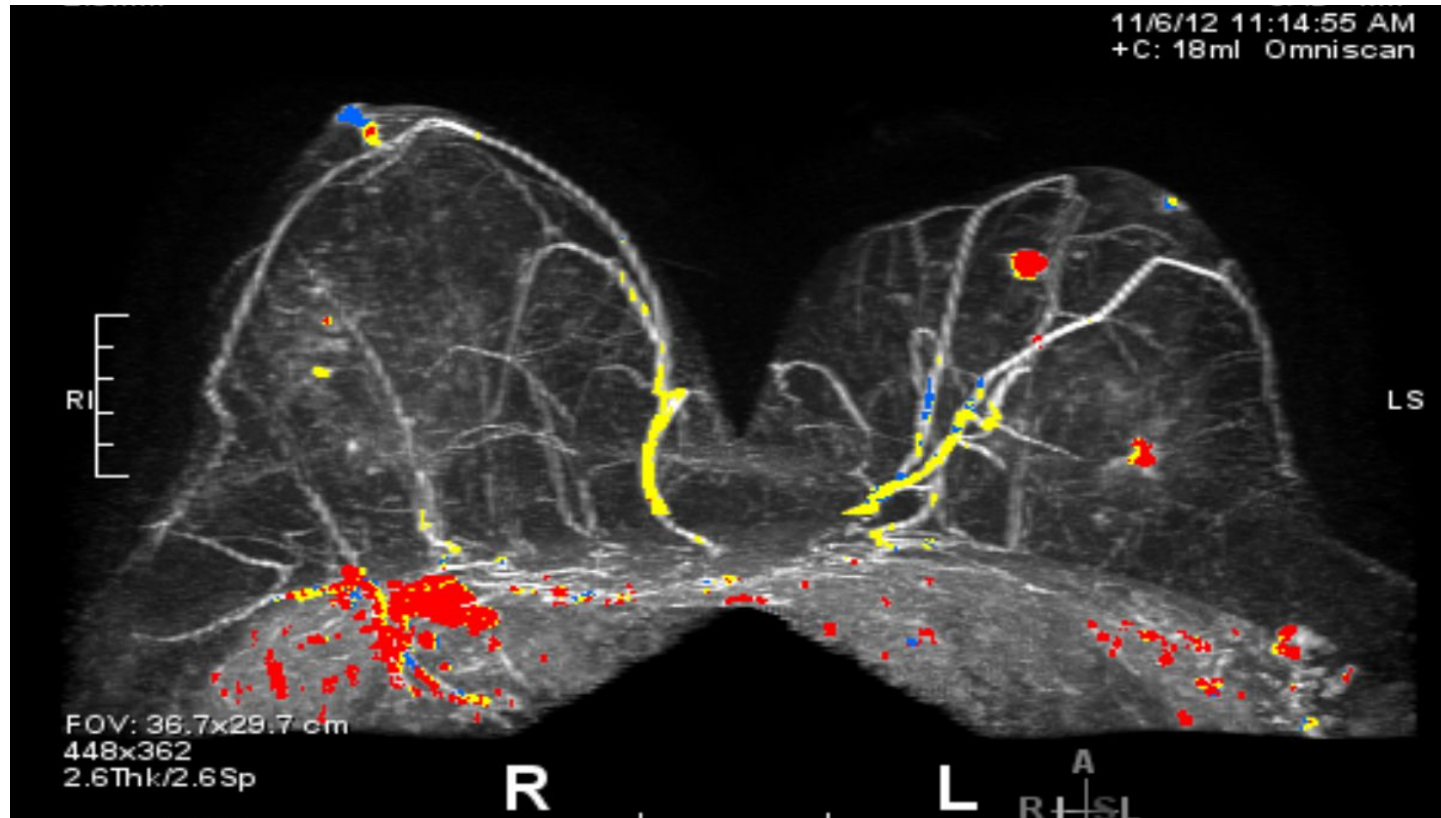


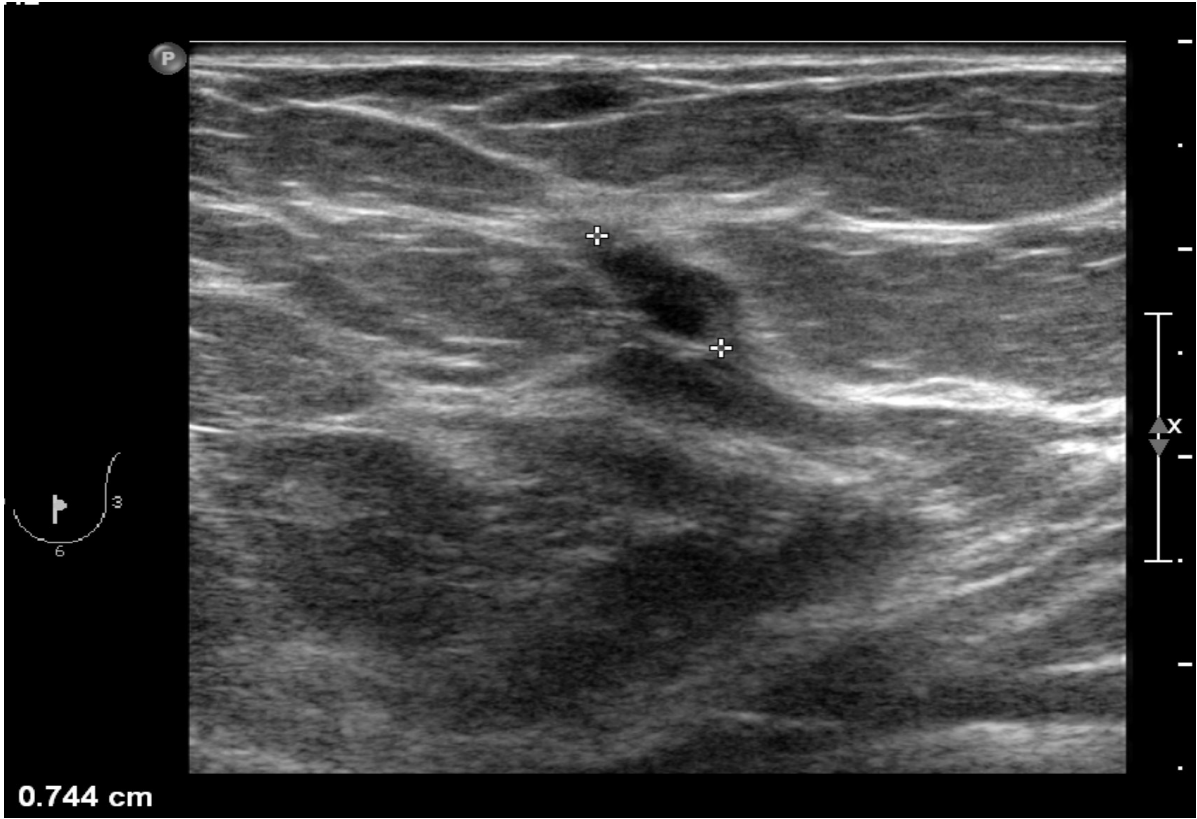


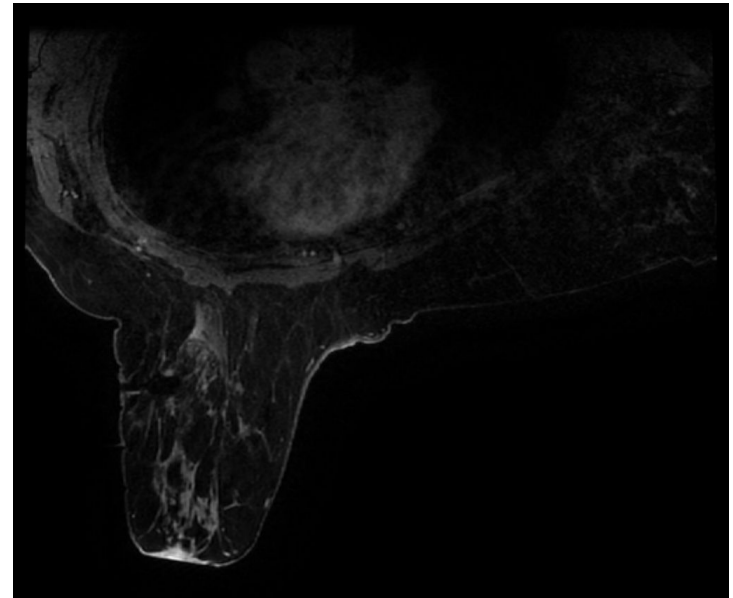
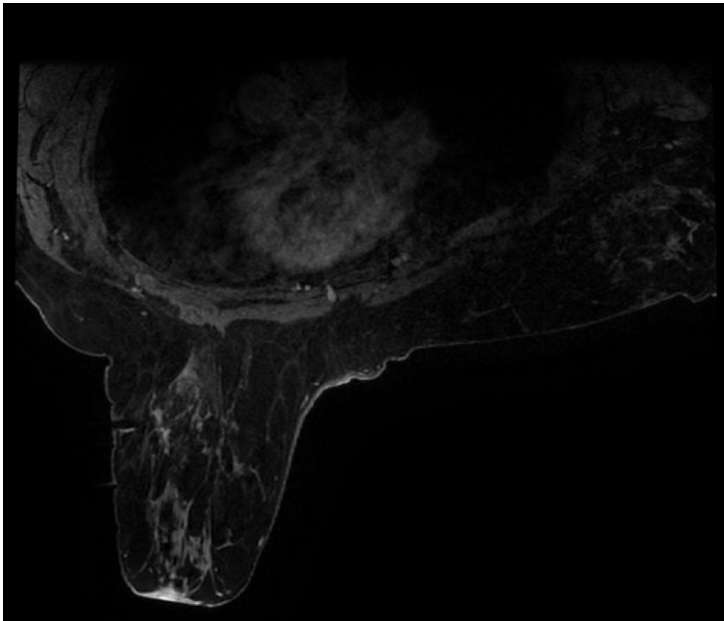
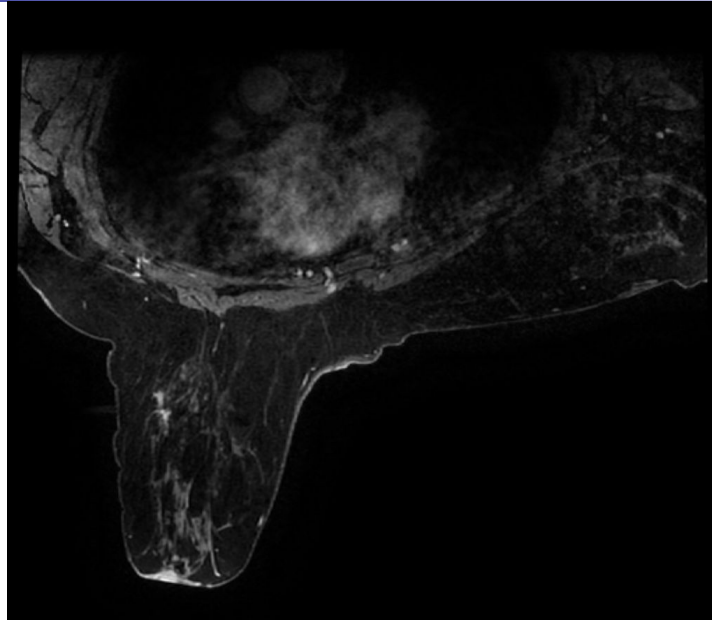
- 62 år
- Känd:
 - metastas i höger axill









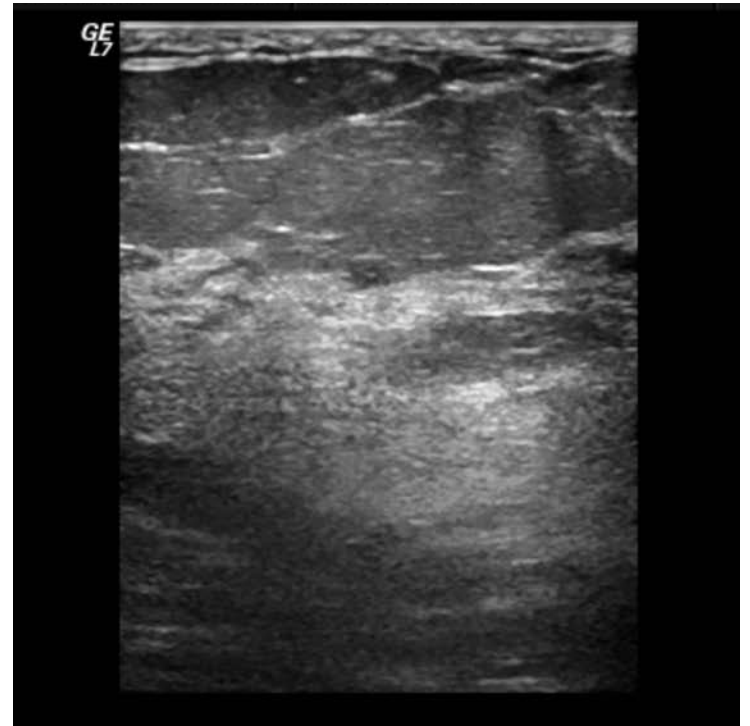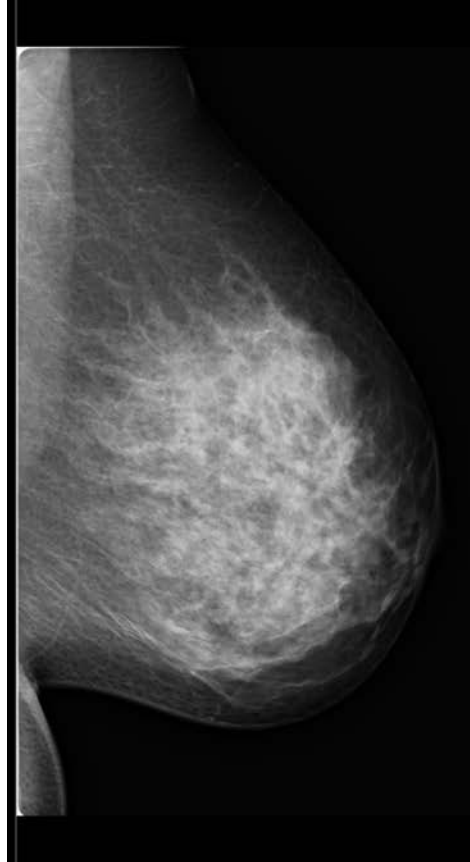
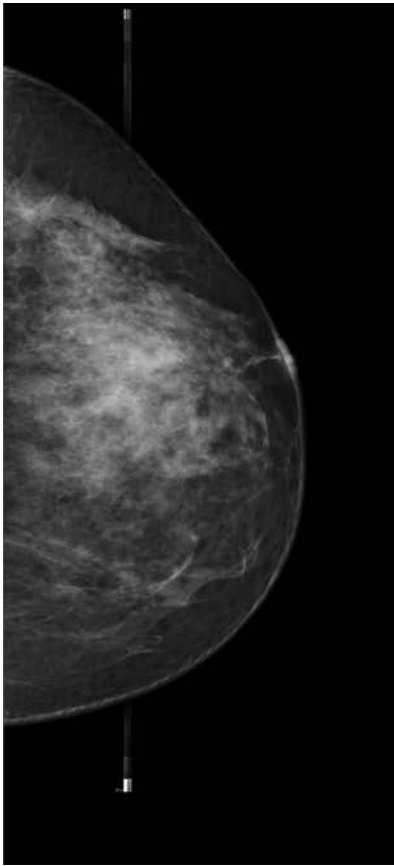


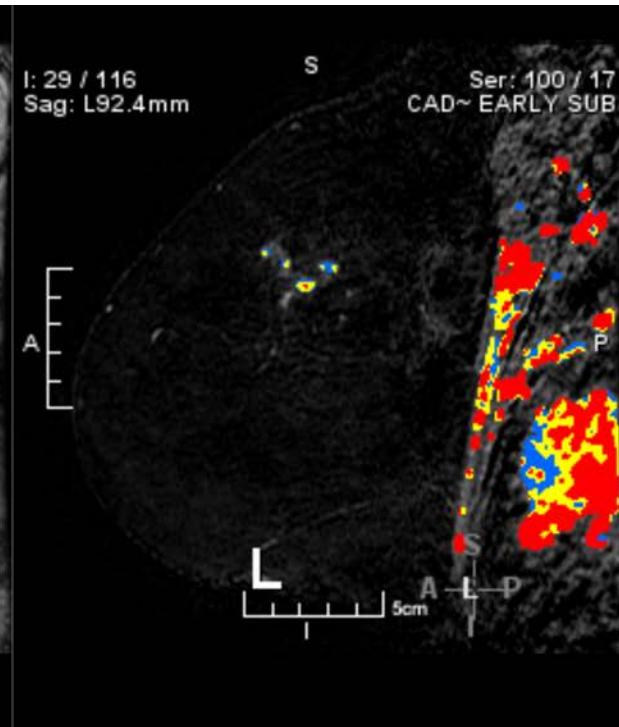
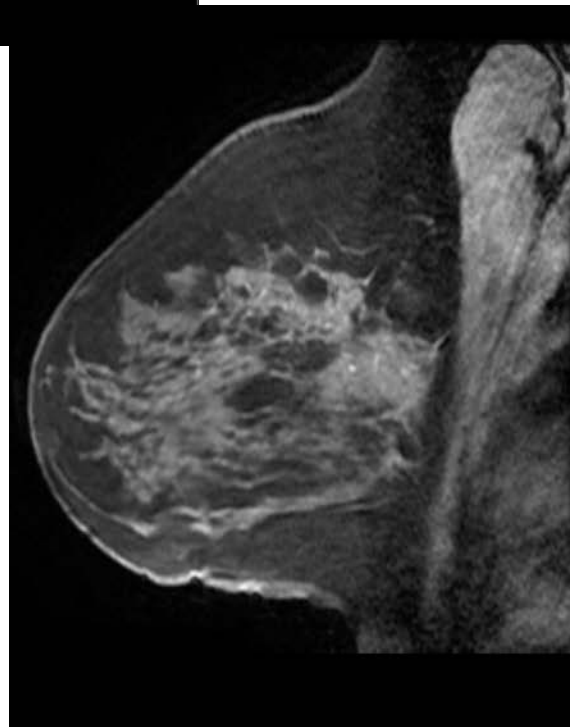
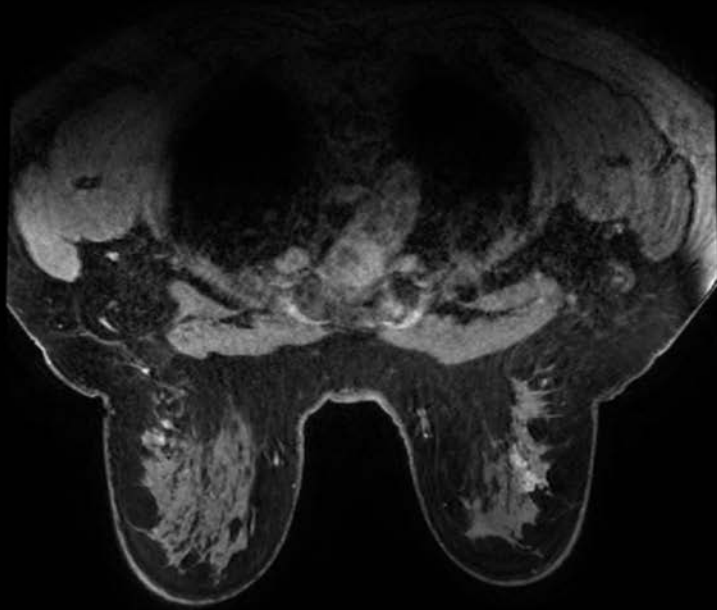


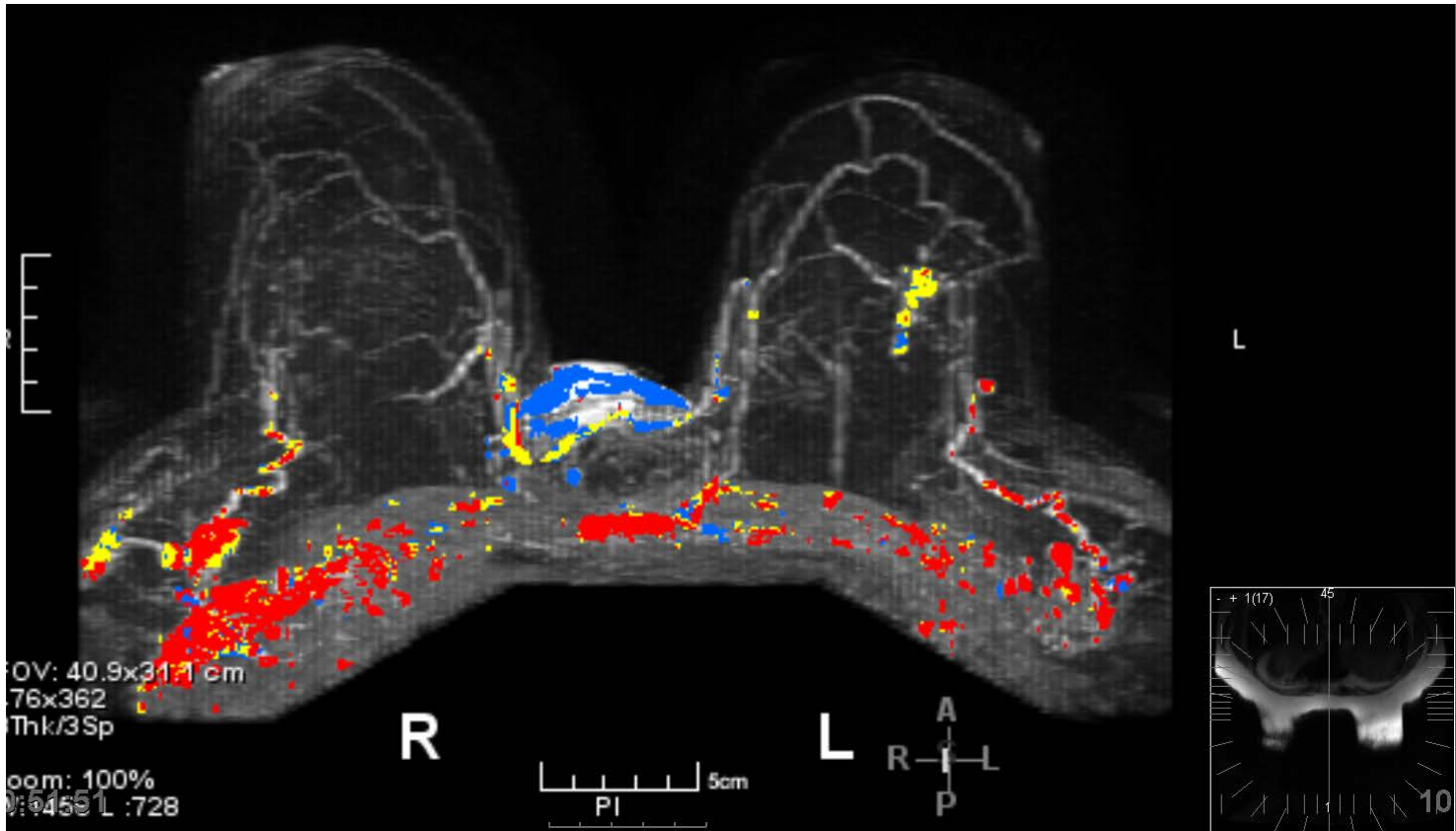
- 39 år

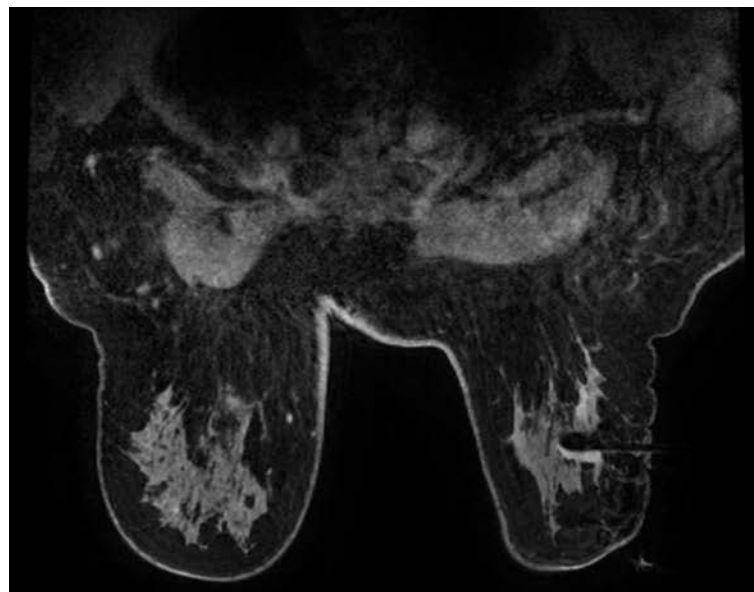
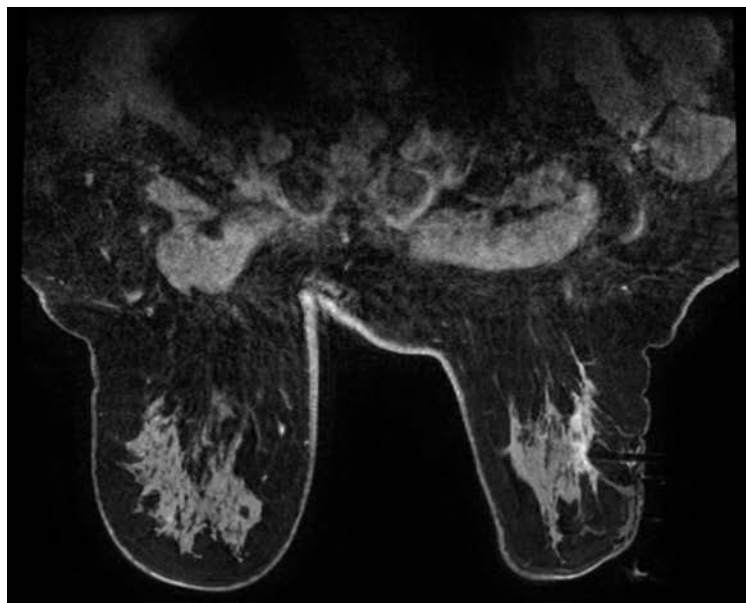
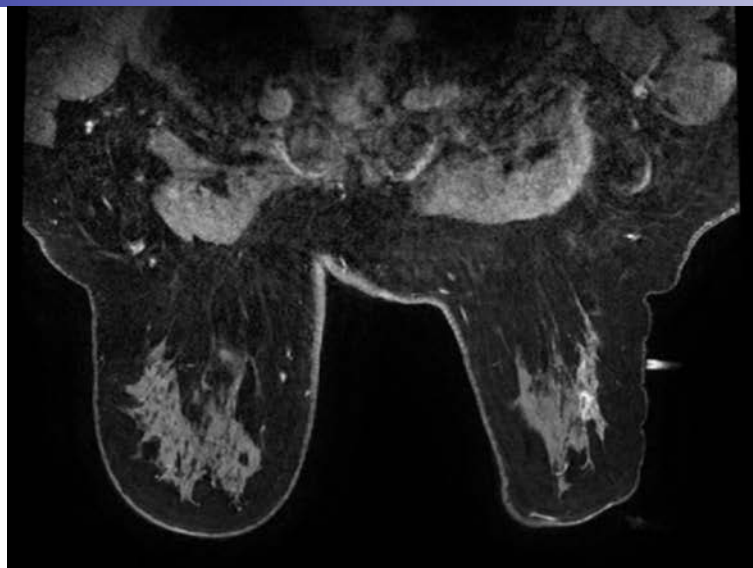
- Känd:


 - blodig sekretion ur vänster
bröstvårta

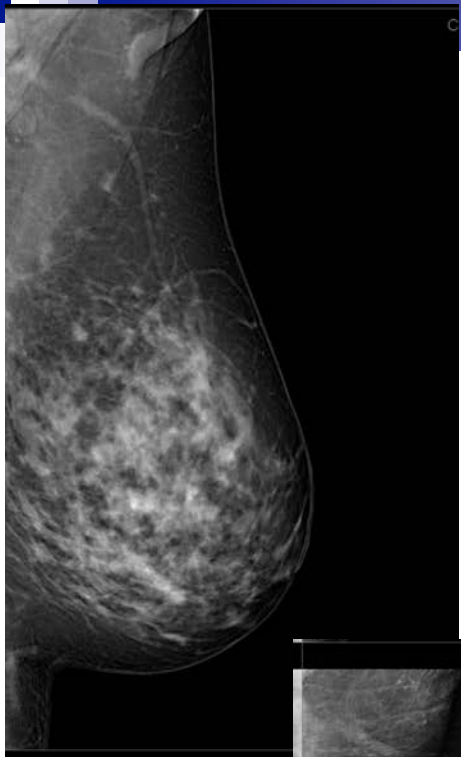



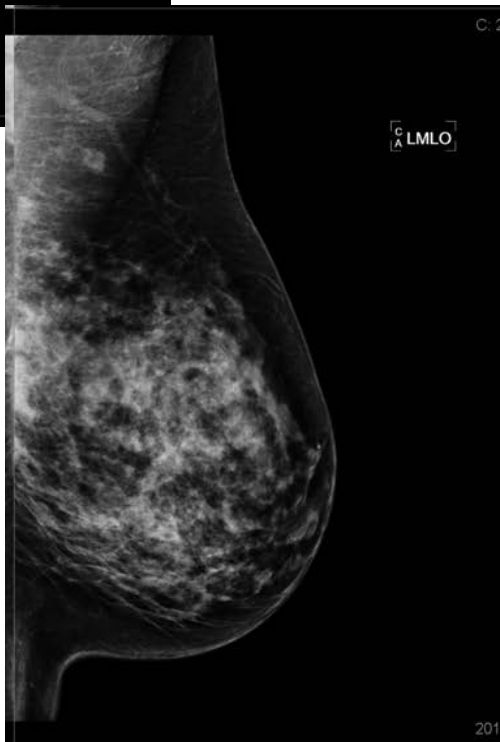
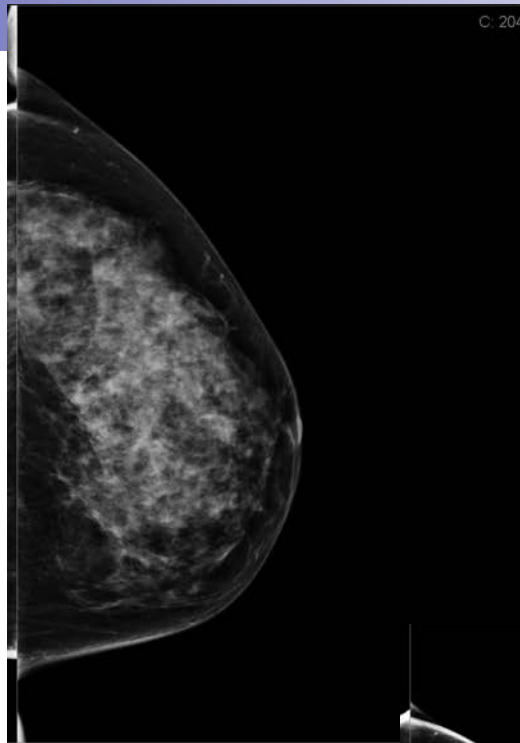




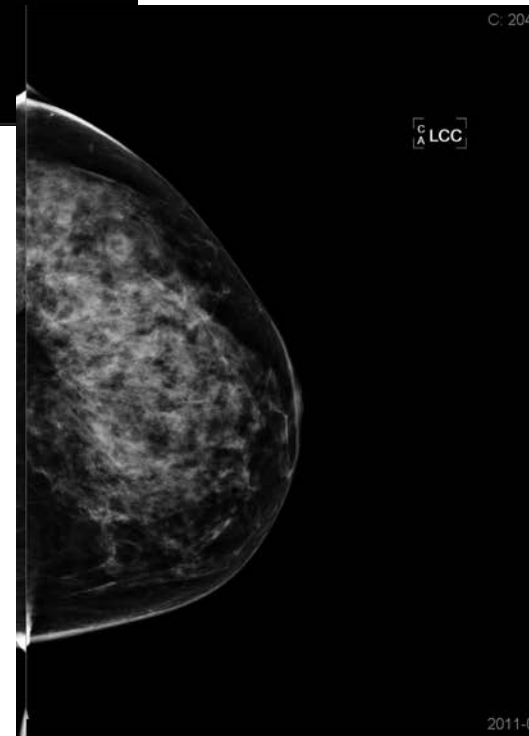
- 
- 55 år
 - Screening patient
 - Diagnostisk sektor

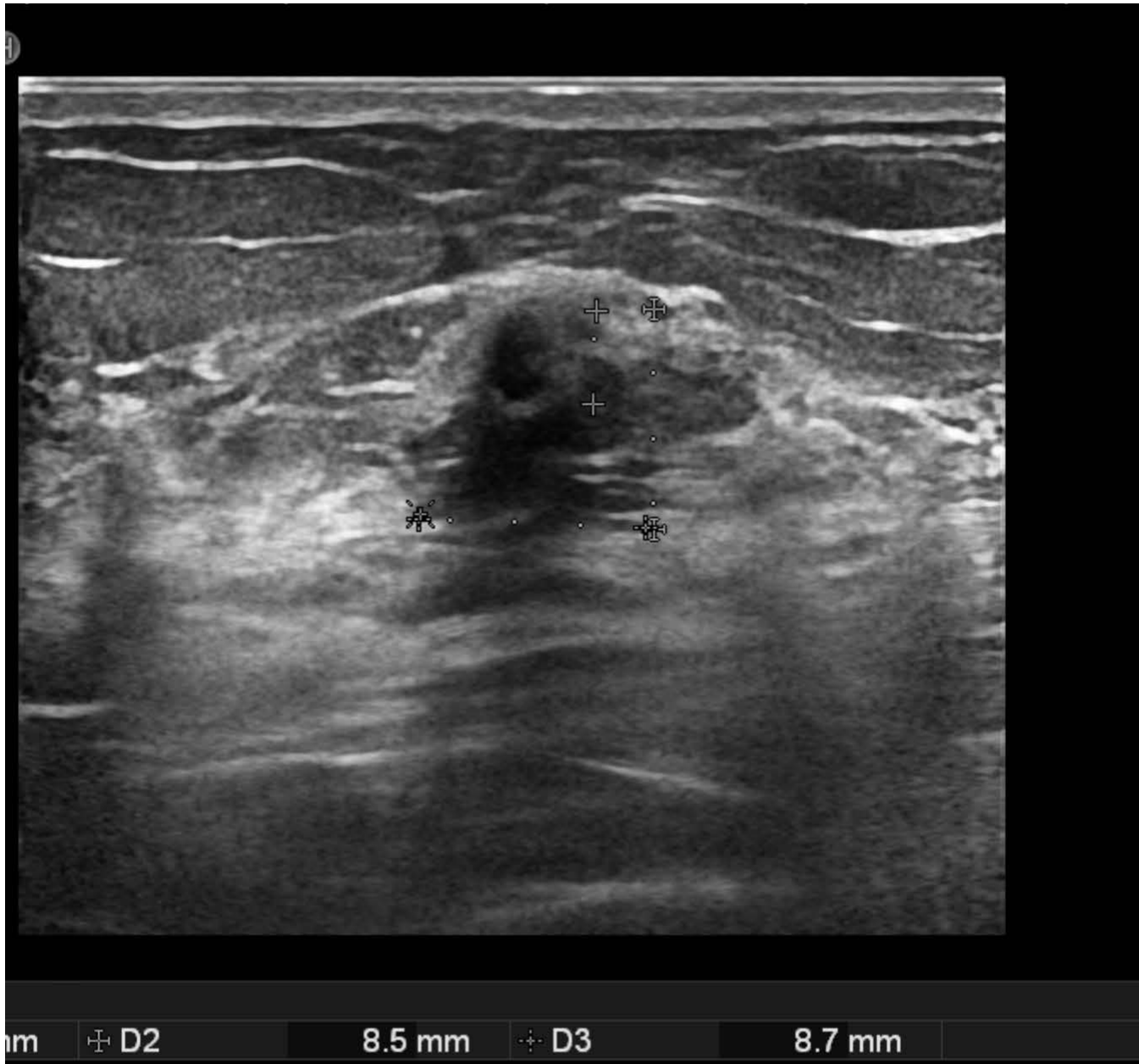


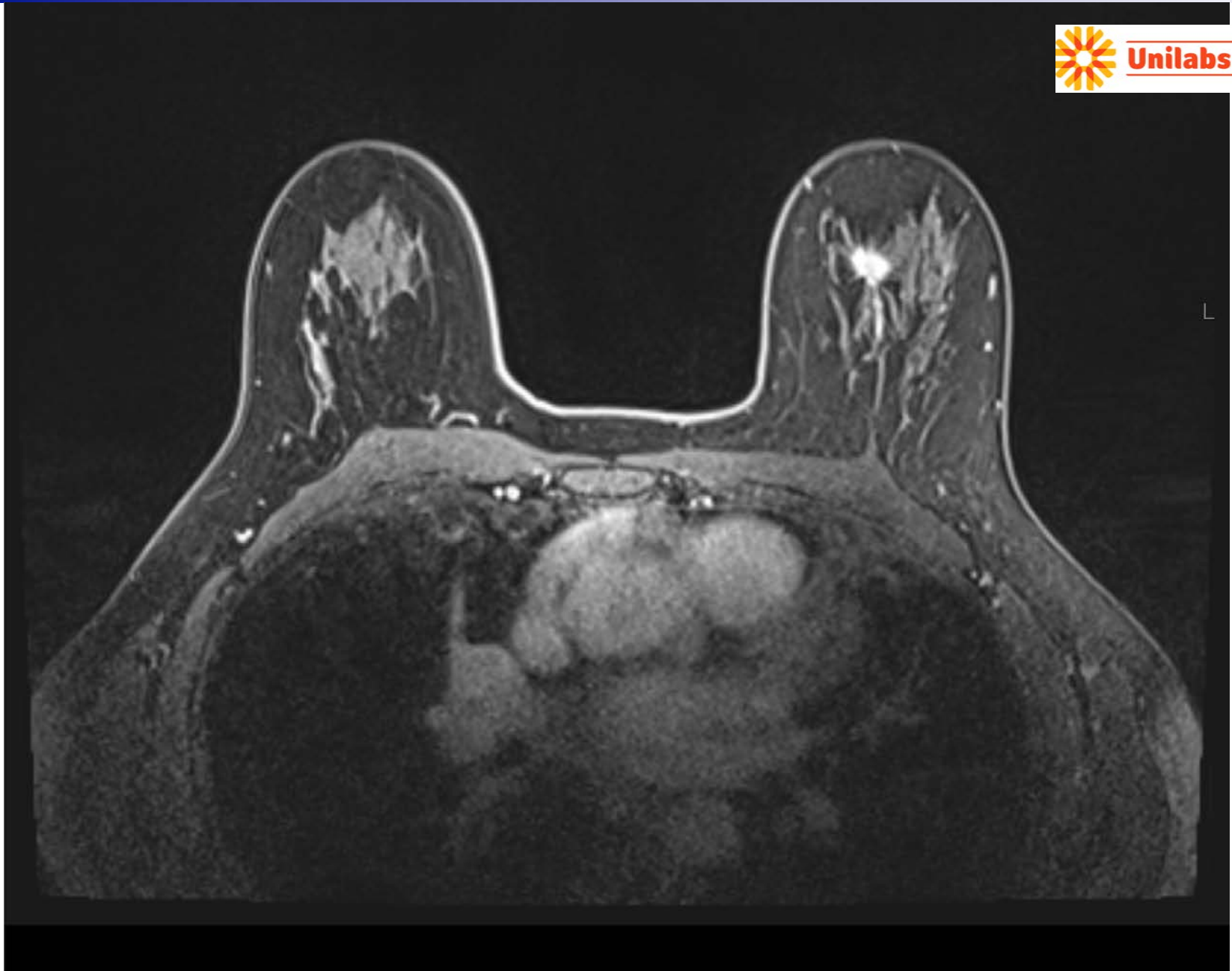2013

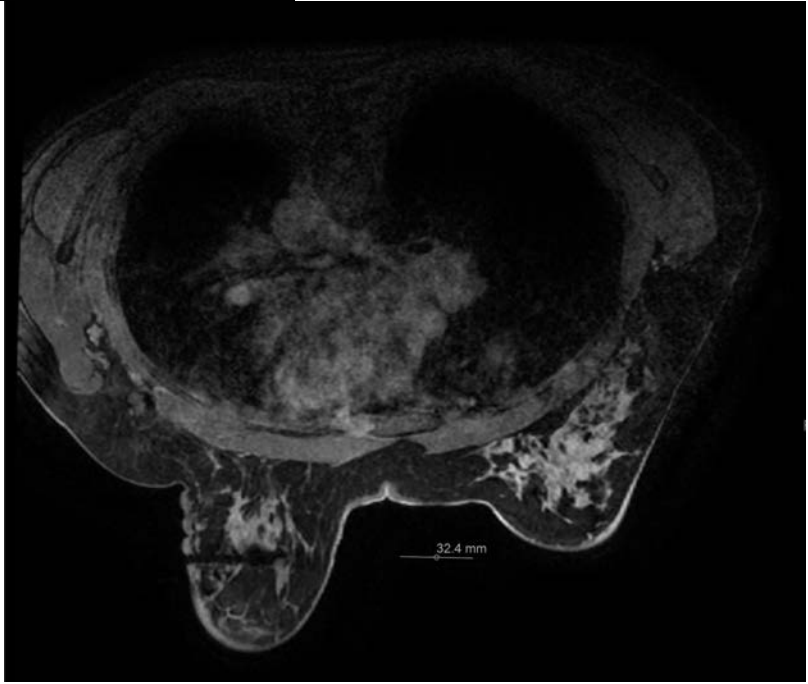
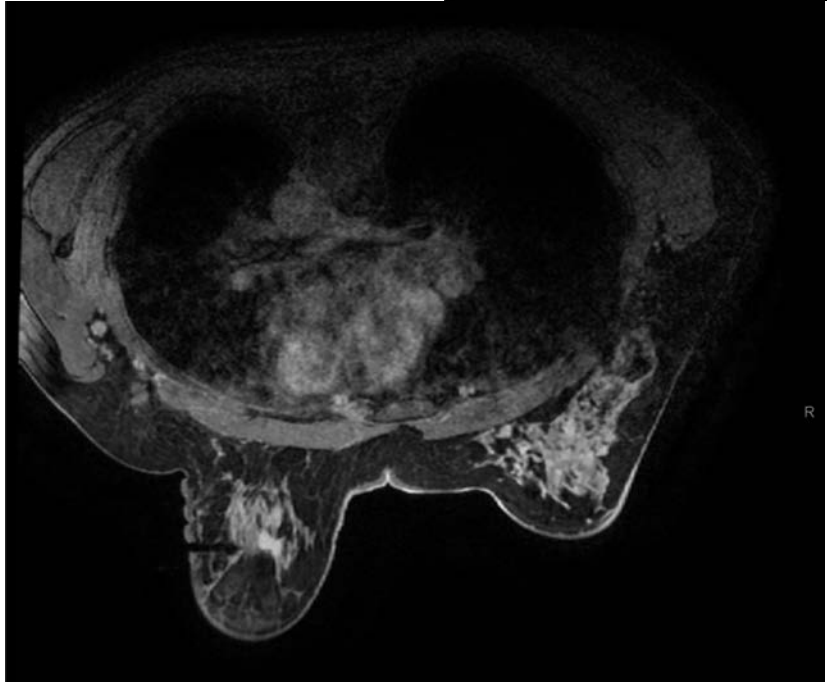
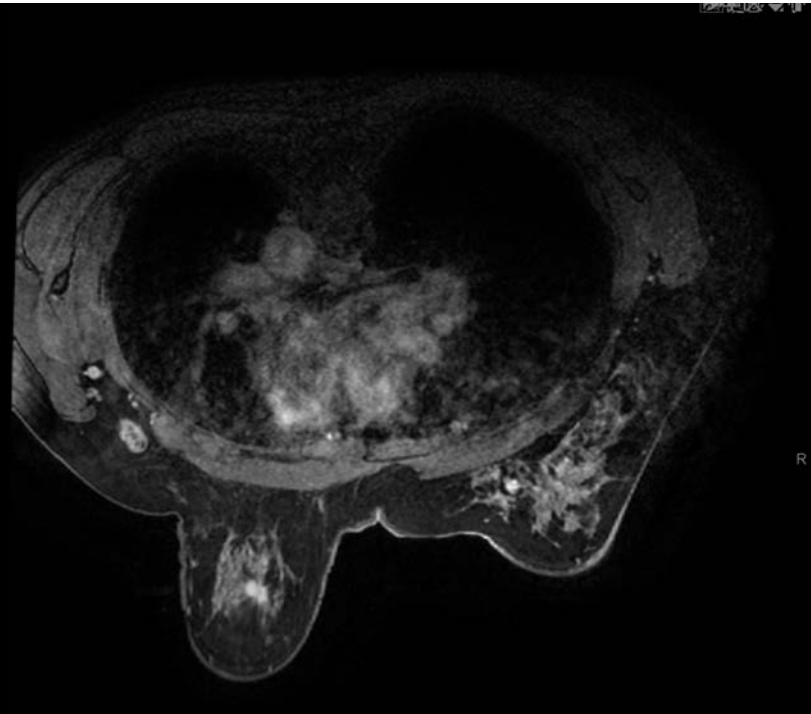
2011









Frågestund.....

- Tack!

